

# insight

Vol. XXIX No. 2

JUNE 2011

Scientific Journal of  
**MEDICAL & VISION RESEARCH FOUNDATIONS**  
18, COLLEGE ROAD, CHENNAI - 600 006, INDIA

## Editorial

**Perspective — Oculofacial aesthetics for ophthalmologists —** *Shubhra Goel - Department of Oculoplasty and Oculofacial Aesthetics*

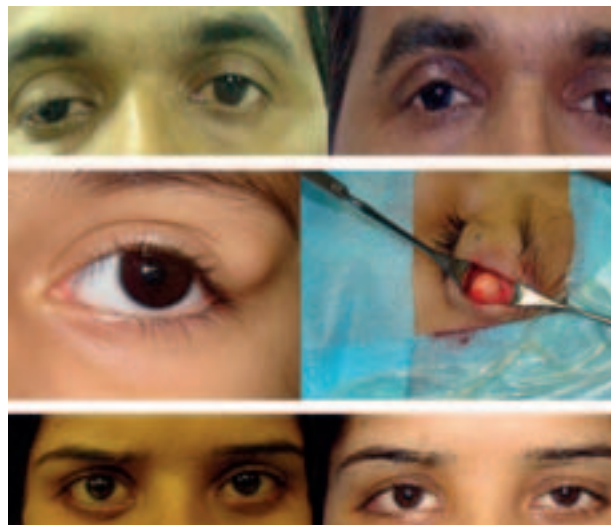**Prosthetic replacement of the ocular surface ecosystem (PROSE) treatment —** *Rajeswari Mahadevan - Medical Research Foundation*

**Conjunctival Mullerectomy for Mild Ptosis — A Case Report and Review of the Literature —** *Mangesh Dhobekar - Oculoplastics, Shubhra Goel - Associate Consultant, Department of Orbit, Oculoplasty and Facial Aesthetics*

**Introduction to Biostatistics-8 — Part III. Inferential Statistics —** *M. Thennarasu, Vishnu Vahan Prasan, and R.R. Sudhir - Department of Preventive Ophthalmology (Biostatistics and Epidemiology), V.V. Jaichandran - Department of Anaesthesiology*

**Muscle Puzzle —** *R. Srikanth and S. Meenakshi - Department of Pediatric Ophthalmology, Medical Research Foundation*

**Retinal Nerve Fibre Layer Analysis Using OCT in Non-Glaucomatous Disease —** *Devendra V. Venkatramani and Rashmin A. Gandhi - Department of Neurophthalmology*



## Editorial

Dear readers

This issue promises to be exciting. Aesthetics is a new area for ophthalmologists and the perspective article introduces the readers to new concepts and procedures. Scleral contact lenses, which are now available for select cases, are described in the next article. A case report of conjunctival mullerotomy follows. The continuing series on biostatistics covers parametric and non-parametric tests. A muscle puzzle follows to let the readers put on their thinking hats. This issue concludes with a technology update on non-glaucomatous indications of RNFL analysis.

S. Meenakshi  
Editor

Shubhra Goel  
Associate Editor

June 2011

## AN APPEAL

A lot of things in this world depend on money - security, shelter, education and even health. But at Nethralaya, money has ceased to be a pre-requisite for sight.

Day after day, year after year, Nethralaya treats hundreds of patients absolutely free of cost and gives them back their sight.

Yet there is no discrimination between the free patient and the one who pays. Apart from the treatment, food, medicines and travel expenses are absolutely free.

Those free patients depend on Nethralaya, and Nethralaya depends on you.

So, come and join the **SANKARA NETHRALAYA OM TRUST INC.**

For questions about tax exempt status and contributions, please contact:

**Mr S V Acharya, Treasurer**

Sankara Nethralaya OM Trust Inc.

9710, Traville, Gateway Drive, Rockville, MD 20850, U.S.A.

Phone: (301)251 0378

INTERNET e-mail : acharya@omtrust.org, snomtrustusa@yahoo.com

www.omtrust.org

For those of you in India and elsewhere, please contact:

**Dr S S Badrinath, President & Chairman-Emeritus**

Sankara Nethralaya

(UNIT OF MEDICAL RESEARCH FOUNDATION)

18 College Road, Chennai 600 006

Phone: 2826 1265, 2827 1616 Fax: (044) 2825 4180, 2821 0117

INTERNET e-mail : chairman@snmail.org

LOOK US UP ON THE WEB at <http://www.sankaranethralaya.org>, <http://www.omtrust.org>

<http://www.supportsankaranethralaya.org>

GIVE ONLINE @ [www.icicicommunities.org](http://www.icicicommunities.org)

Please notify change in your email to : [akila@snmail.org](mailto:akila@snmail.org) (or) [alagiri@snmail.org](mailto:alagiri@snmail.org)

**COME, GIVE THE GIFT OF SIGHT**

# Perspective Oculofacial aesthetics for ophthalmologists

Shubhra Goel

*Department of Neurophthalmology, Medical Research Foundation*

Oculoplasty has traditionally been referred to as the ophthalmic subspecialty dealing with the functional and reconstructive plastic surgery of the eyelids, orbit and tearing system. However, with increasing concerns among the patient populations regarding cosmesis, oculoplasty has now expanded and is known by its subspecialty—oculoplasty aesthetics or oculofacial aesthetics. Oculoplastic surgeons trained in cosmetics or aesthetics are known as oculofacial aesthetic surgeons. Oculofacial cosmetic surgery modifies and reshapes the eyes and the everyday structures of the face that are otherwise functioning normally to improve the appearance and self-esteem of an individual. Lately, oculofacial aesthetics have evoked much interest and importance among ophthalmologists in this area of practice. This article is an attempt made to give an insight into oculofacial aesthetics to all the ophthalmologists interested in this speciality.

India is fast emerging as the hub for medical tourism. The International Society of Aesthetic Plastic Surgery (ISAPS) Global Survey ranked India as the fourth top nation with the most surgical and non-surgical cosmetic procedures being performed in the year 2009–2010. The rapid rise in cosmetic surgical in India has been triggered by factors such as increasing consumer awareness, inspiration from acceptance of these procedures among the working middle class and advances in surgical and non-surgical procedures. It becomes necessary to possess the basic understanding and knowledge of this subject.

As one grows older, the changes that occur in the skin, soft tissue and bony facial skeleton result in the 'aging face' characterized by dermatochalasis, brow ptosis, fat prolapse, infraorbital hollows, fine and deep wrinkles, skin lines and pigmentation. In a world where first impressions have become increasingly important and are governed by an individual's perception of age, there is an increasing demand from patients for enhanced aesthetic results without any downtime and minimal adverse effects. These aging changes can be very well corrected with the minimally invasive cosmetic procedures with minimal downtime.

Cosmetic procedures can be broadly classified as surgical and non-surgical methods.

## SURGICAL METHODS

### Blepharoplasty

Blepharoplasty is currently the most common incisional facial aesthetic surgery that is being performed worldwide. Aging brings about many changes in the periocular region: descent of the brow, dermatochalasis, weakening of the orbital septum and herniation of the orbital fat,

degenerative changes in the thin eyelid skin marked by the appearance of fine rhytids (wrinkles) and aponeurotic ptosis. Many of these issues can be tackled with blepharoplasty, either singularly or in combination with additional cosmetic procedures. The standard skin approach, upper eyelid blepharoplasty, is a fairly simple procedure. Fat sculpting may be done after skin and orbicularis removal and helps to decrease the heaviness of the upper lid.

In the lower eyelid, the relaxation of the orbicularis oculi, orbital septum and skin leads to the protrusion of the intraorbital fat, resulting in the formation of eyelid bags. The traditional pinch skin approach, lower eyelid blepharoplasty, involves removal of extra skin, with or without fat sculpting. The excision or sculpting of fat can also be performed via transconjunctival approach. Repositioning of the herniated fat into the subperiosteal space is a more conservative approach. This also helps in correction of the lower eyelid hollows or tear trough deformity and redistribution of the fat in the lower eyelid. Besides this, horizontal lid tightening and stabilization are fundamental to lower eyelid blepharoplasty.

### Brow lift

Brow ptosis is another common cosmetic problem that occurs as the skin ages and fascial attachments weaken. The absence of the frontalis muscle lateral to the temporal fusion line allows the brow and preseptal fat pads to slide over the temporalis fascial plane and push the lateral brow segment downward. Repeated facial expressions such as frowning, squinting and eyebrow elevation may also accelerate this process. Brow ptosis leads to pseudo-dermatochalasis and even to the exaggeration of the existing dermatochalasis. This is not only cosmetically bothersome to the patient, giving a depressed and sleepy look, but also leads to limitation of the peripheral field of vision. In addition, there may be forehead ptosis and eyelid ptosis and hence a complete evaluation of the patient is a must. There are several surgical approaches for eyebrow and forehead repositioning, from the more traditional coronal lift, pretrichial lift, forehead lifts, midforehead lifts and direct brow lifts to the newer less-invasive endoscopic brow lift, internal browpexy and chemical brow lift.

### Midface lift (suborbicularis oculi fat lift)

The layer of fat found posterior to the orbital portion of orbicularis oculi in the lower eyelid is termed as suborbicularis oculi fat (SOOF). The midfacial fat is attached to the orbicularis via a superficial aponeurotic system.

As aging occurs, the orbicularis weakens and droops. Along with this, the SOOF and the cheek fat pad descend. As the orbicularis weakens and a midface ptosis develops, the midfacial fat is pulled caudally, giving rise to a 'tired' appearance. Bone loss and fat atrophy accentuate the hollows in the infraorbital region between the eyelid and the cheek, and exaggeration of the nasolabial fold further emphasizes this degeneration. The procedure may be approached via the eyelid or with a combined temporal endoscopic approach with access to the cheek through the eyelid or the buccal gingival sulcus.

### Face lift

Face lifting has evolved significantly, from the era of total and composite rhytidectomy to more recent minimally invasive techniques to plicate or resect the superficial musculoaponeurotic system. In the MACS (minimal access cranial suspension) lift, vertical suspension of the descended SMAS is achieved through plication with purse-string sutures and anchoring to the temporalis fascia through preauricular and temporal hairline incisions. Two to three purse-string sutures are typically placed for correction of neck and lower face descent. For midfacial ptosis, an additional suture suspends the malar fat pad. For patients with severe facial aging and descent, minimally invasive approaches may not be adequate.

## NON-SURGICAL METHODS

### Oculofacial rejuvenation

Skin resurfacing and facial rejuvenation have been used for many years in the treatment of rhytids, scars and photodamage to the skin. Commonly performed procedures include Botox, dermal fillers and others such as mechanical dermabrasion, chemical peeling and lasers.

### Botox

Botulinum A exotoxin (Botox) has been used in facial rejuvenation and cosmetic oculofacial treatments. It is produced by the Gram-positive bacterium *Clostridium botulinum* and derives its activity from its ability to block the release of acetylcholine from the presynaptic terminal of the neuromuscular junction.

Botox A has been used in the treatment of dynamic fine lines of expression such as glabellar frown lines, crow's feet, horizontal forehead lines and smoker's lines and in chemical brow lifts and elevation of the corners of the mouth. The other uses include correction of jowls, platysmal bands and axillary hyperhidrosis. The injections are very safe in experienced hands; however, few side effects such as mild pain and bruising at the injection site may be observed. In rare situations, incomplete response, ptosis and other complications may be observed due to local spread of the chemical. Currently, common commercial botulinum toxin preparations are available: Botox (botulinum toxin type A; Allergan, Irvine, CA), Dysport (type A toxin—hemagglutinin complex; Ipsen,

UK) and Myobloc (type B toxin, injectable solution; San Francisco, CA).

### Dermal fillers

Fillers assist in reshaping the face and restoring the bony contours and lines. The ideal desired characteristics for soft-tissue fillers are that they must be safe, biocompatible, easy to inject, readily prepared, easy to store and affordable, have long-lasting cosmetic effects and must not provoke any complications. They are used for the treatment of deep wrinkles and static rhytids. Static rhytids refer to wrinkles at rest, grooves, furrows and fine lines that are the result of aging, sun exposure and loss of skin and muscle elasticity. The deep glabellar furrows, transverse crease over the bridge of the nose ('Bunny lines'), nasolabial and melolabial folds ('Marionette lines'), and perioral lines are the most popular areas for filler injections with satisfying results. Other indications are the midface rejuvenation to restore the lost volume due to either age-related changes or diseases causing lipodystrophy. Many materials, such as hyaluronic agents, calcium hydroxyapatite, injectable bovine collagen, injectable poly-L-lactic, silicone acid and autologous fat, have been used. The current state-of-the-art fillers include non-animal-derived stabilized hyaluronic acid (NASHA) products such as Restylane, Juvederm, Perlane, Radiesse, and Sculptra.

### Microdermabrasion

The technique of microdermabrasion involves mechanical removal of layers of skin using abrasives such as aluminium crystals. The recent technology incorporates the infusion anti-aging agents into the skin. Being a superficial treatment, it causes less discomfort, has lesser risks and has a faster recovery time than laser resurfacing. Acne scars, fine rhytids, pigmentation and other damaged skin changes are some of the problems that can be effectively treated with this method. It has also been used in combination with skin laser resurfacing to blend-treated and non-treated regions. Contraindications include recent herpes simplex virus outbreaks, weeping acne, warts, rosacea, unstable diabetes and autoimmune disorders.

### Chemical peels

While microdermabrasion is useful for the more superficial skin lesions, the more abrasive chemical peels are used for deeper photodamage and pigmentary disturbances. These agents act by accelerating the normal process of exfoliation. The depth of penetration of the acid is determined by the concentration, method of application, pretreatment skin and duration of contact with the skin. In addition to the correction of pigmentation, the remodelling of collagen and dermal layers that occurs during the process of healing corrects finer rhytids and restores facial harmony. The peels can be superficial peels or deep chemical peels depending on the layer of the treatment. The most frequently used

superficial peels are the alpha-hydroxyl acids, of which glycolic acid (10%), salicylic acid, phytic acid and trichloroacetic acid are widely used. Trichloroacetic acid (30–50%) and phenol are used to treat severe photodamage and are deeper penetrating peels. Superficial peels with glycolic acid may be used in multiple treatment sessions for reduction of wrinkling and pigmentary irregularities.

## Lasers

Lasers achieve skin tightening, hair removal or pigment and vascular treatment, and can be divided into ablative and non-ablative lasers. They are used for overall skin rejuvenation as well as for selective lesion treatment. Ablative lasers heat and vaporize the water in the superficial skin layers in contrast to the non-ablative treatments that coagulate deeper epidermal and dermal tissues without removing the superficial tissue. The gold standard ablative laser is the CO<sub>2</sub> 1060 nm, while non-ablative lasers include Nd:YAG 1064, 1450 nm, Diode 810 nm, Q-switched ruby 694 nm, Erb:YAG 294 nm and Er:Glass 1540 nm. Laser therapies can be organized based on the chromophores they stimulate. The pulsed dye lasers target haemoglobin and melanin, whereas the Nd:YAG laser is absorbed more readily by water. The CO<sub>2</sub> laser also has water as an absorptive target. More recent approaches to laser skin treatment have included non-ablative technologies that selectively treat the dermis while leaving the epidermis intact. Each of these methods is effective for improving skin aesthetics and has its own limitations.

## Radiofrequency lid tightening

Radiofrequency devices deliver volumetric and uniform heating to the dermis with simultaneous cooling of the skin. These generate heat based on the natural resistance of the tissue to the movement of electrons within a radio-frequency field. The heat causes collagen shrinkage and new collagen deposition, thus tightening and texturing the skin. The FDA-approved 'Radiaage' is inexpensive, easy to use, safe for all skin types and has lesser risk of burns due to better control of skin surface temperature.

## Autologous fat transfer

Like dermal fillers, fat transfer provides volume to areas of relative atrophy due to facial aging. It is natural, safe and long-lasting compared with some fillers. Fat is harvested using liposuction techniques, mixed with saline and injected in a multilayer fashion. Grafted fat improves the quality of aged, scarred skin and heals radiation damage and chronic ulcers, as it has been hypothesized to contain stem cells. The mechanism of fat graft survival and how grafted fat causes these tissue changes is not

clear, and the role of adipose-derived stem cells and preadipocytes in fat survival is a matter of ongoing research.

Fat exhibits many of the qualities of an ideal filler and does more than just filling the area into which it is placed. It is autologous and completely biocompatible, available in sufficient quantities in most patients, naturally integrated into the host tissues, removable if necessary and, by all indications, potentially permanent.

A combination of the various above-mentioned procedures tailored to an individual's needs is used to achieve excellent cosmetic results.

## Cosmeceuticals

Cosmeceuticals (or alternatively, cosmaceuticals) are topical cosmetic-pharmaceutical hybrids intended to enhance beauty through ingredients that provide additional health-related functions or benefits. They are applied topically as cosmetics, but they contain ingredients that influence the skin's biological function. There is a huge market for time-tested products to improve skin-related issues such as pigmentation, scars and photodamage along with signs of aging. Many clients prefer this modality of treatment as it is home-based.

The success of a cosmetic procedure depends on patient satisfaction rather than on anatomic restoration of tissues, and hence it is important to have an insight of the patients' perception of their own appearance, motivation for seeking treatment and expectations of the surgery. Ideal candidates are patients with specific complaints about their appearance and wanting to change pertinent aspects of their anatomy, having realistic expectations of the procedure and clearly understanding the limitations of the procedure.

Cosmetic eyelid and facial surgery, or oculofacial surgery, is without doubt the most rapidly growing sub-discipline of ophthalmic plastic surgery. With advancement in surgical techniques and increasing aesthetic awareness among the patients in recent times, it is certainly going to evolve to become an essential part of ophthalmic practice. It is essential to bear in mind that cosmetic surgery requires empathy, awareness of patient's expectations, comprehensive patient education and appropriate technically skilled surgery with a high benefit to risk ratio.

## Contact Information

Shubhra Goel

DO, DNB (Gold Medalist), MNAMS, FMRF (Oculoplasty), Fellow Ophthalmic Facial Plastic Surgery and Aesthetics - University of Wisconsin, USA.

Department of Oculoplasty and Oculofacial Aesthetics  
No. 73, Venkata Krishna Road,  
Raja Annamalaipuram,  
Sankara Nethralaya  
Chennai - 600028.  
Email: drsgl@snmail.org

# Prosthetic replacement of the ocular surface ecosystem (PROSE) treatment

Rajeswari Mahadevan

Medical Research Foundation, Sankara Nethralaya, Contact Lens Clinic & PROSE Clinic,  
41/18, College Road, Chennai – 600006

## HISTORICAL BACKGROUND

Scleral contact lenses retain a small but unique place in contact lens practice. There are instances where visual rehabilitation is possible only with the use of scleral lenses. Scleral lenses were originally made with blown glass in the 1880s.<sup>1,2</sup> The mechanical fitting principles and oxygen deprivation were the limiting factors. In the 1930s, many worked on impression techniques. PMMA was an added bonus for impression fitting in the 1940s, due to its machinability and thermostatic properties. Fenestrated sclerals resolved some problems due to oxygen deprivation.<sup>3</sup>

## ORIGIN OF BOSTON SCLERAL LENS

Perry Rosenthal worked further upon the work of Australian optometrist Don Ezekiel, who reported success with an air-ventilated silicone acrylate scleral lens in 1983. His work was toward the aim of finding a protective system to deliver medication to eyes with severe inflammation. Their pioneering work began in the late 1980s and led to the development of the Boston Scleral Lens (Dk 100)t, Boston Foundation for Sight.

Prosthetic replacement of the ocular surface ecosystem (PROSE) treatment was earlier called as BSLPD, which is Boston scleral lens prosthetic device. The BSLPD was the first fluid-ventilated scleral lens designed to enclose a bubble-free reservoir of oxygenated aqueous fluid maintained at neutral hydrostatic pressure over the corneal surface. By avoiding the intrusion of air bubbles, its fluid reservoir functions as a liquid corneal bandage that offers unique therapeutic benefits for managing severe ocular surface disease in addition to its traditional role of masking irregular corneal astigmatism.

**Treatment Description:** PROSE is a pioneering treatment model developed by Boston Foundation for Sight (BFS) to restore vision, support healing, reduce symptoms and improve quality of life for patients suffering with complex corneal diseases. PROSE uses FDA-approved (1994) custom-designed and fabricated prosthetic devices to replace or support impaired ocular surface system functions that protect and enable vision.

## BENEFITS

PROSE can

- reestablish a healthy and stable ocular surface environment that supports healing and reduces symptoms,
- improve blurry vision by masking surface corneal irregularities and transmitting a sharp image to the back of the eye and
- prevent damage by protecting and shielding the cornea and conjunctiva against the environment and eyelids.

For many of the thousands of patients suffering with complex corneal diseases, PROSE may be the ideal, and sometimes only, treatment capable of restoring vision and dramatically reducing eye pain and light sensitivity.

## INDICATIONS

### Ocular surface disease

Sjögren's syndrome; history of LASIK or other refractive surgeries; limbal stem cell deficiency; Stevens-Johnson syndrome (SJS)/toxic epidermal necrolysis syndrome (TENS); aniridia, cicatricial conjunctivitis/ocular

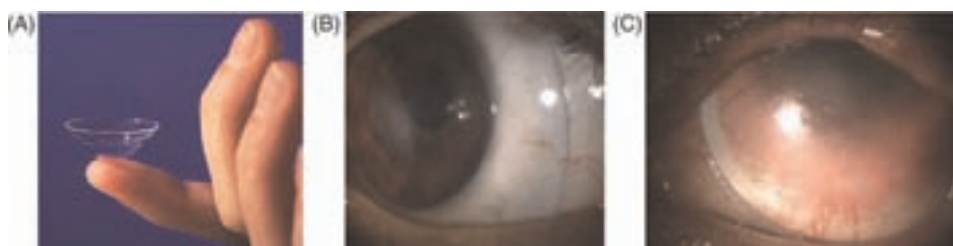

Figure (A) Scleral lens; (B) PROSE in Keratoconus eye; (C) PROSE in SJS eye.

cicatricial pemphigoid; chemical/thermal injury; post-surgical corneal exposure/lagophthalmos, anatomic paralytic; acoustic neuroma; dry eye syndrome; chronic ocular graft versus host disease (GVHD).

### Corneal ectasia/irregular astigmatism

Keratoconus; keratoglobus; pellucid marginal degeneration; Terrien's marginal degeneration; Salzmann's nodular degeneration; Meesmann's corneal dystrophy; post-operative astigmatism; corneal transplant (penetrating keratoplasty or PK, PKP); radial keratotomy (RK); photorefractive keratectomy (PRK); phototherapeutic keratectomy (PTK); epikeratophakia; LASIK; open globe injury; corneal scarring after trauma after infection; corneal degenerations and dystrophies

The following issues are considered while determining patients' qualifications for PROSE:

- Despite the high oxygen transmissibility, endothelial functions must be robust. Preexisting microcystic corneal oedema is a contraindication. The central corneal thickness of eyes that have undergone PKP against that of those with corneal endothelial disease is monitored during the fitting process to confirm the presence of adequate functional endothelial reserve. Scleral lenses are contraindicated for failing grafts.
- In some patients with excessive tear debris, the fluid reservoir may have to be replaced periodically when it becomes sufficiently turbid to interfere with vision.
- Patients need to master the technique of bubble-free insertion and removal.

### DEVICES USED IN PROSE

The prosthetic devices used in PROSE are transparent domes, about the size of a nickel, made of specialized plastic that allows oxygen to reach the cornea. They are filled with sterile saline that remains in the reservoir while the devices are being worn during waking hours.

PROSE creates

- a new transparent, smooth optical surface over the irregular, damaged or diseased cornea and
- an expanded artificial tear reservoir that provides constant lubrication while maintaining necessary oxygen supply.

Prosthetic devices have three important zones performing different functions:

*optic zone* – replaces the optical power of a healthy cornea in combination with the fluid reservoir,

*transitional zone* assures sufficient vault over any cornea shape, independent of base curve and

*haptic zone* maximizes ocular surface system function by precisely aligning the shape of the hepatic bearing with the shape of the patient's eye.

The mathematical description of contours using spline functions that are integral to the *Design to fit* (DTF)<sup>TM</sup> CAD/CAM system allows prosthetic devices to be created of almost infinitely variable shapes with smooth transitions between zones.

## TREATMENT PROCESS

PROSE interdisciplinary treatment teams include an optometrist, a cornea specialist ophthalmologist(s), who has completed an intensive 9-week PROSE Clinical Fellowship, medical assistants, trainers, and prosthetic device-manufacturing engineers and technicians. PROSE treatment teams work with each patient, his/her support system and other medical providers to form a collaborative care network in which all members work to understand the patient's specific needs and reach treatment goals together.

The practitioners use BFS' proprietary DTF CAD/CAM system to directly control the design and assure that each prosthetic device precisely fits the patient's unique eye shape and maximizes ocular surface system function. Devices are manufactured at BFS' state-of-the-art laboratory in Needham, MA, using Precitech ultra-precision diamond Nanoform computerized numerical command (CNC) lathes, which are typically used to manufacture high-tech parts for the aerospace industry.

## SANKARA NETHRALAYA – MEDICAL RESEARCH FOUNDATION, CORNEA & CONTACT LENS CLINIC – PROSE CLINIC

### Steps in the Treatment Process

- Referral from primary eye-care provider, medical doctor or cornea specialist (from Sankara Nethralaya or outside clinics and hospitals)
- Initial consultation visit—to review the suitability of the device.
- PROSE treatment (10–15-day-long visits) or set of 2–4 days' visit with intervals.
- Periodic follow-up visits as required during the first 6 months.
- Annual medical evaluation of PROSE treatment.

The same device can be used as long as it is in good quality and as long as the eye parameters remain the same.

### Contact Information

Medical Research Foundation  
Sankara Nethralaya  
Contact Lens Clinic & PROSE Clinic  
41/18, College Road  
Chennai – 600006  
Tamilnadu  
India

Email: graji@snmail.org, cl@snmail.org

Rajeswari Mahadevan  
Ms. Juliet/Ms. Rati/Ms. Flora  
Mobile: 9383571539  
Phone: 91-44-42271930, 91 44 -28271616. Extension: 1241

## BOSTON FOUNDATION FOR SIGHT

Boston Foundation for Sight (BFS) is an internationally renowned not-for-profit eye health care organization

specializing in complex corneal disease research, education, treatment and patient care. Its 13,000 square foot facility in Needham, MA, includes a state-of-the-art manufacturing laboratory, a medical institute staffed with seven doctors and a dozen technicians/trainers, a Clinical Research Center and a new Patient and Community Support Center.

Visit their website, [www.bostonsight.org](http://www.bostonsight.org), for more information.

## REFERENCES

1. Kalt E. *Reported by Panas P*. Bull Aced Med 1888;19:400. [English translation by Pearson RM, Kalt E. Keratoconus and the contact lens. Am J Optom Vis Sci 1989;66:643.]
2. Fick AE. *A contact lens*. Arch Ophthalmol 1888;19:215-226.
3. Bier N. *The practice of ventilated contact lenses*. Optician 1948;116:497-501.
4. <http://www.bostonsight.org>
5. <http://www.bostonsight.org/?pg=683&pgtitle=About-our-Treatment>



# 2011

# 1<sup>st</sup> OFISA CON

Chennai, September 3-4, 2011

## Principles and Practice of Ophthalmic Anaesthesia

### PROGRAMME HIGHLIGHTS

**Workshop in regional anaesthesia**

Anatomy for needle blocks  
Needle blocks: Techniques  
Sub-Tenon's block : Wet lab  
Eye-POD (Practicing orbital device): Simulation in regional blocks

**Session Themes**

Challenges to Ophthalmologists and Anaesthesiologists in Ophthalmic anaesthesia  
Systemic and ophthalmic complications in Ophthalmic anaesthesia  
"Near-misses" and surprises in Ophthalmic Anaesthesia  
Controversies in Ophthalmic anaesthesia  
Anaesthesia for Specialist eye surgery  
Current concepts and future of Ophthalmic anaesthesia

**Polling-On-Spot survey - Interactive Session**

On cut-off point for Blood pressure, glucose level and renal parameters for eye surgery

**Ophthalmic Quiz**

Eligibility criteria : Trainee (Anaesthesiology or Ophthalmology)  
Team : 2 members in each team

**Free paper presentation**

Case report or clinical studies pertaining to ophthalmic anaesthesia  
Abstract (300 words) can be submitted on-line

**Early bird registration ends: 15th July 2011**

Registration for Workshop is for limited delegates only.....  
first come first serve basis!

VENUE: Sri. V.D. Swami Auditorium



**INTERNATIONAL FACULTY**



**Prof Chris Dodds**  
The James Cook University  
Hospital Middlesbrough, UK



**Prof Chandra M Kumar**  
The James Cook University  
Hospital Middlesbrough, UK



**Prof Ezzat Aziz**  
Cairo University, Egypt



**Dr K L Kong**  
Secretary SOAS  
Sandwell and West  
Birmingham Hospitals NHS Trust



**Dr Oya Yalcin Cok**  
Baskent University, School  
of Medicine Ankara, Turkey



**Dr Phil Guise**  
Auckland City Hospital,  
New Zealand



**Prof Steven Gayer**  
University of Miami Miller  
School of Medicine Florida, US



**Dr Shashi B Vohra**  
Birmingham  
and Midland Eye Centre, UK



**Dr Tom Eke**  
Consultant Ophthalmologist,  
Spire Newcastle Hospital, UK



**Dr. Thomas Tjahjono**  
Wink Mata Nusantara  
Jakarta, Indonesia

**For further details contact:**  
**Dr Jaichandran V V**  
Organizing Secretary  
Mobile No : +91 9884096860  
Email: [dvrod@snmail.org](mailto:dvrod@snmail.org)

**Ms. S. Prasanna Lakshmi**  
Conference Secretary  
Medical Research Foundation  
Phone: +91 44 43084222  
Mobile No : +91 8939784176  
Email: [prasanna@snmail.org](mailto:prasanna@snmail.org)  
[www.ofisa.sankaraneethalaya.org](http://www.ofisa.sankaraneethalaya.org)



# Conjunctival Mullerectomy for Mild Ptosis A Case Report and Review of the Literature

Mangesh Dhobekar<sup>1</sup> and Shubhra Goel<sup>2</sup>

<sup>1</sup>Oculoplastics, Sankara Nethralaya

<sup>2</sup>Department of Orbit, Oculoplasty and Facial Aesthetics

## Abstract

A 25-year-old woman with mild ptosis of left upper eyelid since five years came for a cosmetic enhancement. Patient had mild ptosis with good levator function and a positive phenylephrine test. Conjunctival Mullerectomy procedure resulted in the desired correction. A review of literature of the conjunctival Mullerectomy procedure is presented.

**Keywords:** Mild Ptosis, conjunctival Mullerectomy, Phenylephrine test

## CASE REPORT

A 25-year-old lady visited us with complaint of drooping of her left upper eyelid since 5 years. Patient had developed left side Bell's palsy 5 years ago, following which she noticed her left side looking smaller. On examination, her best corrected visual acuity was 6/6; N6 in both eyes. She had normal intraocular pressures, with no afferent pupillary defect, and the ocular motility was full in both eyes. Posterior segment was normal. Patient had left upper eyelid mild ptosis with margin reflex distance 5 mm on right side and 3.5 mm on left side. Right upper lid excursion was 17 mm and the left upper lid excursion was 14 mm. Orbicularis Oculi muscle tone was normal and Bell's phenomenon was good on both side. The phenylephrine test was positive in the left eye. With topical instillation of 10 % phenylephrine eye drops in the upper conjunctival fornix three times every 5 minutes, the margin reflex distance improved to 5 mm from baseline 3.5 mm measurement (Figures 1 and 2). Based on this, conjunctival mullerectomy ptosis correction procedure was planned on the left side under local

anesthesia. Postoperatively, patient was achieved the desired cosmetic results (Figures 3 and 4).

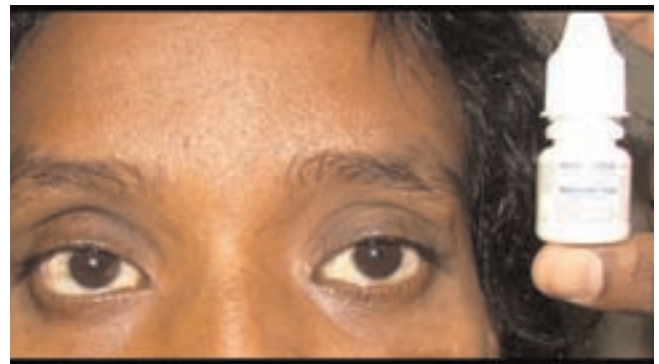

Figure 2. Left eye- Positive response to 10 % phenylephrine.

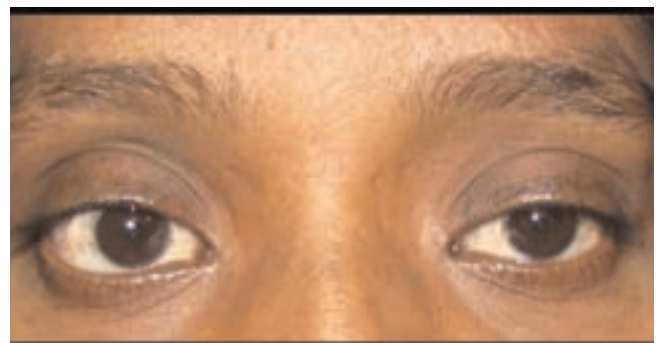

Figure 3. Left eye - mild ptosis.

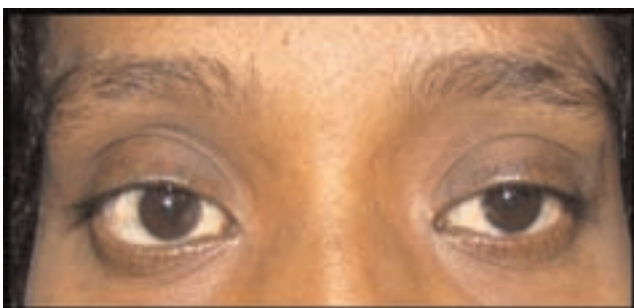

Figure 1. Left eye- mild ptosis

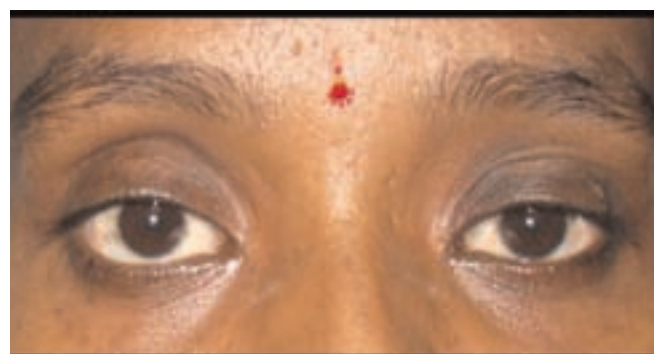

Figure 4. Left eye- Good ptosis correction following Conjunctival Mullerectomy.

## PROCEDURE

Local infiltration was administered over the everted upper eyelid using 0.5 ml of 2 percent lidocaine and 0.5 percent bupivacaine solution with 1:100,000 units of epinephrine. A 4-0 silk suture traction suture was passed at the central lid margin, to evert the lid over a Desmarres's retractor. A unipolar radiofrequency cautery was used to mark half the distance (4mm) of desired resection (8mm) from the upper border of the tarsus toward the superior fornix. 6-0 silk suture was passed horizontally through conjunctiva and Mullers muscle in three passes along these marks. The silk sutures were elevated equally and a Putterman's Mullerectomy clamp was placed to incorporate Muller's muscle and conjunctiva (Figure 5). A 5-0 prolene suture was passed from lateral to medial through conjunctiva and Muller's muscle 1.5 mm below the clamp in a serpentine fashion. Both ends of the suture were externalized through opposite ends to tie on the skin. A 15 number blade was used to excise the conjunctiva and Muller's muscle (Figure 6). Prolene suture ends were tied on the skin. Haemostasis was achieved. Antibiotic ointment was applied Postoperatively patient was advised to start ice compressions 10 minutes every waking hour for first 48 hours then to start warm compresses 3 times a day for 2 weeks. Patient was started on tear supplements and analgesic medications. Prolene sutures were removed after 7 days. Postoperatively, patient achieved the desired



Figure 5. The T shaped- Putterman clamp grasping a pre-determined amount of Muller's muscle and conjunctiva.

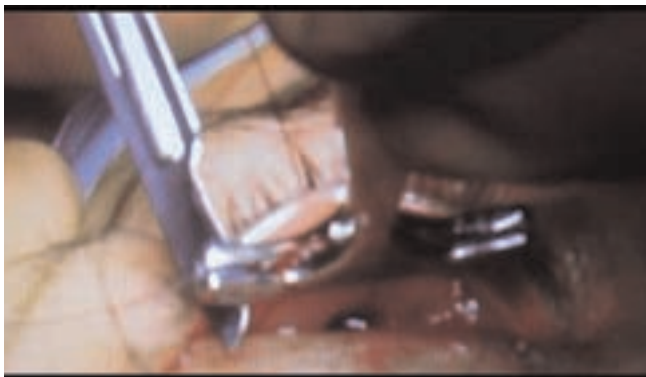


Figure 6. A pre-determined amount of Muller's muscle and conjunctiva is being resected by a No. 15 surgical blade.

cosmetic results with comparable lid height and contour (Figure 4).

## DISCUSSION

First described by Putterman and Urist<sup>1,2</sup> Muller's muscle conjunctival resection (MCR) has been a trust worthy technique for selected cases of acquired, anophthalmic, and congenital blepharoptosis repair with mild to moderate degree of ptosis, good levator excursion and positive phenylephrine test. Muller muscle is a sympathetically innervated eyelid elevator. Originating from the undersurface of the levator palpebralis superioris, it is approximately 12 mm in length and inserts on the superior tarsal border; stimulation results in upper eyelid elevation of approximately 2 to 3 mm<sup>3</sup>. Kiyoshi<sup>4</sup> reported that conjunctival Mullerectomy procedure involves Muller's muscle acting as a spindle in a stretch reflex involving involuntary contraction of the levator muscle to control the upper eyelid height.

Various modifications of conjunctival Mullerectomy have been used to treat ptosis, each using different algorithms of resection for similar degrees of ptosis. Weinstein and Buerger<sup>5</sup> proposed a linear relationship between the amount of MM resection and ptosis correction. Their technique used 8 mm of resection to correct 2 mm of ptosis, then added or subtracted 1 mm of resection to adjust the eyelid position by 0.25 mm. Dresner<sup>6</sup> described an algorithm of 4 mm of for 1 mm of ptosis, 6 mm of MCR for 1.5 mm ptosis, 10 mm of MCR for 2 mm ptosis and 11 or 12 mm MCR for more than 3 mm of ptosis. Guyuron and Davies<sup>7</sup> reported a modification to the Putterman's technique of MCR that involved resection of 6 to 9 mm of tissue within the T shaped clamp (with no tarsal resection) followed by wound closure with a 6/0 running horizontal mattress suture. Lake et al<sup>8</sup> used an open-sky method of conjunctival Mullerectomy for the correction of ptosis with moderate to good levator function without the use of the T shaped clamp specially designed by Putterman and found it to be effective in treating ptosis with negative phenylephrine test. A further improvement to the open-sky technique of conjunctival Mullerectomy was reported by Khooshabeh et al.<sup>9</sup> Foster et al<sup>10</sup> reported a novel technique of conjunctival Mullerectomy using fibrin sealant instead of suture for wound closure.

## THE IMPORTANCE OF THE PHENYLEPHRINE TEST

In Putterman's original description of the surgical technique of conjunctival Mullerectomy 10% phenylephrine eye drops were instilled preoperatively into the upper conjunctiva fornix to elicit the response of Muller's muscle contraction to lift up the eyelid.<sup>11, 12</sup> The phenylephrine test functions as a guide to the amount of MM and conjunctiva resection required based on the treatment algorithm adopted by the surgeon. Glatt et al<sup>13</sup> reported that although the 10% dosage resulted in a statistically significant upper eyelid elevation of 0.2 mm higher than the 2.5% dosage, but the small magnitude might not be of clinical importance in influencing the decision to perform conjunctival Mullerectomy or the amount of tissue resection.

## THE ADVANTAGES OF CONJUNCTIVAL MULLERECTOMY

External levator advancement or resection has been the gold standard for the treatment of ptosis with moderate to good levator function.<sup>14,15</sup> In contrast, MCR seems more predictable and rarely requires re-operation<sup>16,17</sup>. Ben Simon et al<sup>18</sup> compared the 2 procedures and reported a significantly lower re-operation rate of 3% in the MCR group versus 8% in the external ptosis surgery group. Compared to Fasanella-Servat procedure the tarsus is preserved in MCR with less risk of suture keratopathy since the sutures are placed at the superior tarsal border and at a higher level away from the cornea. Eyelid contour abnormality and the potential risk of tarsal instability are additional disadvantages that can be avoided with MCR. MCR also has the advantages of less tissue dissection, avoidance of a potential cutaneous incision scar, a shorter operation time (approximately 20 minutes per eyelid) and obviating the need for intraoperative adjustment and patient cooperation.<sup>19</sup>

## THE DISADVANTAGES OF CONJUNCTIVAL MULLERECTOMY PROCEDURE

One of the disadvantages of conjunctival Mullerectomy is conjunctival fornical shortening due to conjunctival resection. This problem has especially more impact on disease states with conjunctival deficiency such as anophthalmic socket, cicatrizing conjunctival diseases such as Steven Johnson syndrome and ocular cicatricial pemphigoid. However, caution should be exercised in patients with glaucoma filtration surgery such as trabeculectomy and filtration tubes to avoid infections although suture keratopathy is very rare. Dry eye is another concern with MCR especially with an increased surface area of tears evaporation due to a widened palpebral fissure post-operatively. Dailey et al<sup>20</sup> reported no effect on tear production (as measured by Schirmer's test) after MCR, although subjective dry eye symptoms were transiently increased in the immediate postoperative period.

## CONCLUSION

Conjunctival Mullerectomy is a easy, safe, predictable and effective treatment alternative for mild to moderate ptosis with moderate to good levator function.

## REFERENCES

1. Putterman AM, Urist MJ. Müller muscle- conjunctival resection. Technique for treatment of blepharoptosis. *Arch Ophthalmol* 1975;93: 619-23.
2. Putterman AM, Urist MJ. Müller's muscle-conjunctival resection ptosis procedure. *Ophthalmic Surg* 1978;9: 27-32.
3. Beard C. Muller's superior tarsal muscle: anatomy, physiology and clinical significance. *Ann Plast Surg* 1985;14:324-33.
4. Kiyoshi M. Stretching the Muller muscle results in involuntary contraction of the levator muscle. *Ophthalmic Plast Reconstr Surg* 2002;18:5-10
5. Weinstein GS, Buerger GE. The modifications of Muller's muscle conjunctival resection operation for blepharoptosis. *Am J Ophthalmol* 1993; 5: 647-51.
6. Dresner SC. Further modifications of the Muller's muscle-conjunctival resection procedure for the blepharoptosis. *Ophthalmic Plast Reconstr Surg* 1991;7:114-22.
7. Guyuron B, Davies B. Experience with the modified Putterman procedure. *Plast Reconstr Surg* 1988; 82:775-80.
8. Lake S, Mohammad-Ali FH, Khooshabeh R. Open sky Müller's muscle conjunctival resection for ptosis surgery. *Eye* 2003;17:1008-12.
9. Khooshabeh R, Baldwin HC. Isolated Muller's muscle resection for the correction of blepharoptosis. *Eye* 2006 Dec 8; 1-6.
10. Foster JA, Holck DE, Perry JD, Wulc AE, Burns JA, Cahill KV, et al. Fibrin sealant for Müller muscle-conjunctiva resection ptosis repair. *Ophthal Plast Reconstr Surg* 2006; 22:184-7
11. Putterman AM, Urist MJ. Müller muscle-conjunctiva resection. Technique for treatment of blepharoptosis. *Arch Ophthalmol* 1975;93:619-23.
12. Putterman AM, Urist MJ. Müller's muscle-conjunctival resection ptosis procedure. *Ophthalmic Surg* 1978;9:27-32
13. Glatt HJ, Putterman AM, Fett DR. Muller's muscle-conjunctival resection procedure in the treatment of ptosis in Horner's syndrome. *Ophthalmic Surg* 1990;21:93-6.
14. McCulley T, Kersten RC, Kulwin DR, Feuer WJ. Outcome and influencing factors of external levator palpebral superioris aponeurosis advancement for blepharoptosis. *Ophthal Plast Reconstr Surg* 2003;19:388-93.
15. Berlin AJ, Vestal KP. Levator aponeurosis surgery: a retrospective review. *Ophthalmology* 1989;96:1033-6
16. Guyuron B, Davies B. Experience with the modified Putterman procedure. *Plast Reconstr Surg* 1988;82:775-80.
17. Baldwin HC, Bhagey J, Khooshabeh R. Open sky Müller Muscleconjunctival resection in phenylephrine test-negative blepharoptosis patients. *Ophthal Plast Reconstr Surg* 2005;21:276-80.
18. Ben Simon GJ, Lee S, Schwarcz RM, McCann JD, Goldberg RA. External levator advancement vs Müller's muscle-conjunctival resection for correction of upper eyelid involuntal ptosis. *Am J Ophthalmol* 2005;140:426-32.
19. Glatt HJ, Putterman AM, Fett DR. Muller's muscle-conjunctival resection procedure in the treatment of ptosis in Horner's syndrome. *Ophthalmic Surg* 1990;21:93-6
20. Dailey RA, Saulny SM, Sullivan SA. Müller muscle-conjunctival resection: effect on tear production. *Ophthal Plast Reconstr Surg* 2002; 18:421-5.

# Introduction to Biostatistics-8

## Part III. Inferential Statistics

M. Thennarasu<sup>1</sup>, V.V. Jaichandran<sup>2</sup>, Vishnu Vahan Prasan<sup>1</sup> and  
R.R. Sudhir<sup>1</sup>

<sup>1</sup>Department of Preventive Ophthalmology (Biostatistics and Epidemiology)

<sup>2</sup>Department of Anaesthesiology

### INTRODUCTION

In the previous issue, we dealt with various statistical tools used for testing hypotheses with normal data. In this issue, we deal with statistical techniques for testing abnormal (non-parametric) data.

There are two classes of statistical tests: parametric and non-parametric. The word parametric comes from “metric”, meaning to measure, and “para”, meaning beside or closely related; the combined term refers to the assumptions made about the population from which the measurements are obtained. Non-parametric data do not meet such rigid assumptions. They are also referred to as “distribution-free”, i.e. the data can be drawn from a sample that may not follow the normal distribution.

### APPLICATIONS AND USES

The three major parametric assumptions are based on the level of measurement, sample size and normal distribution of the dependent variable. If these assumptions are violated by research in health sciences, then non-parametric tests should be used.

### LEVEL OF MEASUREMENT

When deciding the statistical test to be used, it is important to identify the level of measurement associated with the dependent variable of interest. Non-parametric tests can be used with all levels of measurement and they are most frequently associated with nominal-level and ordinal-level data.

### SAMPLE SIZE

Adequate sample size is another of the assumptions underlying parametric tests. For non-parametric tests,

sample size is not so important, and they can be performed for very small sample sizes. The value of “very small” is not delineated in the literature, but, in general, if the sample size is less than 30, then non-parametric tests can be used.

### NORMALITY

Non-parametric statistics can be applied to data in which the variable of interest does not belong to any specified distribution (i.e. normal distribution).

### USES

1. As non-parametric methods make fewer assumptions, their applicability is much wider than that of the corresponding parametric methods.
2. The use of non-parametric methods may be necessary when data have a ranking but no clear numerical interpretation, such as when assessing preferences, in terms of the levels of measurement, i.e. ordinal data.
3. They can be particularly used when the sample size is small and also when the samples are unequal in size.

### DIFFERENT METHODS OF NON-PARAMETRIC TESTS

There are a wide range of methods that can be used under different circumstances, but some of the more commonly used are the non-parametric alternatives to the *t*-tests, and these are listed in Table 1.

### MANN–WHITNEY U-TEST

This test is an alternative to the independent *t*-test, when the assumption of normality or equality of variance is not

Table 1. Parametric tests and their equivalent non-parametric tests.

Parametric tests	Uses	Equivalent non-parametric tests
Independent sample <i>t</i> -test	Compares the means of two groups	Mann–Whitney <i>U</i> -test
Dependent sample <i>t</i> -test (paired)	Determines the effect of paired samples	Wilcoxon signed-rank test
Karl Pearson’s correlation coefficient test	Measures the linear relationship between two variables	Spearman’s rank correlation coefficient test
One-way ANOVA	Compares three or more groups	Kruskal–Wallis test
Two-way ANOVA	Compares groups classified by two different factors	Friedman test

met. This, like many non-parametric tests, uses the ranks of the data rather than their raw values to calculate the statistic. Since this test does not make a distribution assumption, it is not as powerful as the *t*-test.

### WILCOXON SIGNED-RANK TEST

This test is a non-parametric statistical test used when comparing two related samples or repeated measurements on a single sample to assess whether their population means differ (paired difference test). It can be used as an alternative to the paired Student's *t*-test when the population cannot be assumed to be normally distributed.

### SPEARMAN'S RANK CORRELATION COEFFICIENT TEST

This test measures the relationship between two qualitative and also abnormal quantitative data. It can be used as an alternative to Karl Pearson's coefficient correlation test. The value ranges from  $-1$  to  $+1$ , where  $-1$  indicates a negative correlation and  $+1$  indicates a positive correlation.

### KRUSKAL-WALLIS TEST

This test is used for testing the equality of population medians among groups. It is identical to the one-way ANOVA with the data replaced by their ranks.

Since it is a non-parametric method, it does not assume a normal population, unlike the analogous one-way ANOVA. However, it does assume an identically shaped and scaled distribution for each group, except for any difference in medians.

### FRIEDMAN TWO-WAY ANOVA

This test is a non-parametric test used for testing the difference between several related samples. It is an alternative to the repeated-measures ANOVA, which is used when the same parameter has been measured under different conditions on the same subjects.

## ADVANTAGES OF NON-PARAMETRIC METHODS

1. If the sample is very small, non-parametric tests are useful.
2. They typically make fewer assumptions about the data.
3. They are much easier to learn and to apply compared with the parametric tests.
4. They are useful for dealing with unexpected, outlying observations that may be problematic while using parametric tests.
5. They can sometimes be used to obtain a quick solution with little calculation.
6. Sometimes, the data do not constitute a random variable from a larger population. Nevertheless, certain kinds of non-parametric procedures can be applied to such data using randomization methods.
7. Basic data need not be actual measurements for these methods.

## DISADVANTAGES OF NON-PARAMETRIC METHODS

1. Because the procedures are non-parametric, there are no parameters to be described and it becomes more difficult to make a quantitative statement about the actual statement between the populations.
2. By ranking, the original data are not taken into account.
3. They lack power.
4. Only testing of hypotheses is done and not the estimation of effects.

## CONCLUSION

In conclusion, non-parametric tests can be used with data that belong to the nominal (e.g. characteristics such as right and left and male and female) and ordinal (e.g. mild, moderate and severe) levels of measurement, which may not follow the normal distribution curve or comply with other assumptions required of data analyzed by parametric statistical methods. However, the results obtained from the data analyzed with the non-parametric statistical methods can yield important information about the degree to which qualities of one group of data differ from those of another group of data.

In the next issue, we will deal with the calculation of sample size.

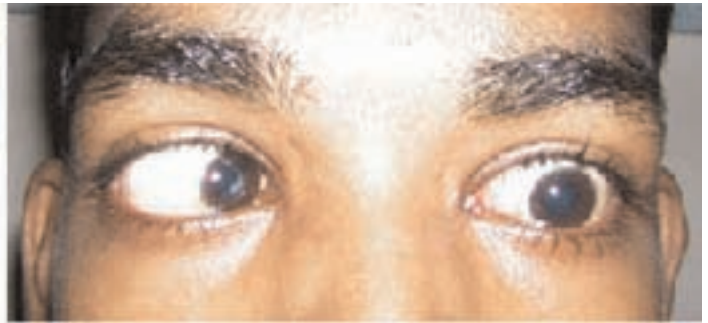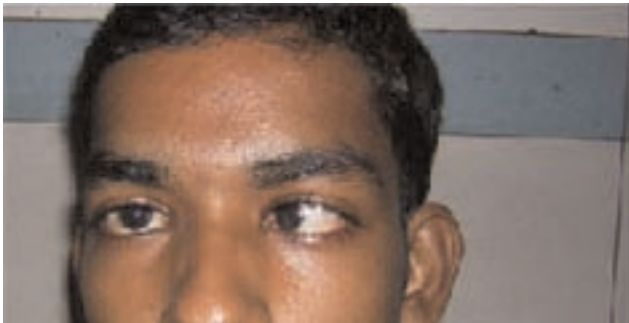# Muscle Puzzle

R. Srikanth and S. Meenakshi

Department of Pediatric Ophthalmology, Medical Research Foundation

A 24-year-old male presents with complaints of left eye squinting inwards from 6 years of age after an episode of fever. Ocular motility examination reveals the presence of large-angle esotropia, which is more on distance

fixation. There is also moderate limitation of abduction in the left eye. Abduction saccades in the left eye were floating.



## WHAT IS YOUR DIAGNOSIS?

Answer available at page 30.

**ARE YOU AN SN ALUMNI ?**  
Don't Miss the Opportunity to Refresh & Sharpen Your Knowledge

**SANKARA NETHRALAYA Alumni**

**SN ALUMNI MEET - 2011**  
Mark Your Calendar

**July 3**  
The Sankara Nethralaya Alumni Academic Meeting

Venue:  
Sri V.D. Swamy Auditorium,  
Sankara Nethralaya, New No.41, Old No.1B,  
College Road, Chennai - 600 006

# Retinal Nerve Fibre Layer Analysis Using OCT in Non-Glaucomatous Disease

Devendra V. Venkatramani and Rashmin A. Gandhi

Department of Neurophthalmology

## INTRODUCTION

Axons of the retinal ganglion cells proceed in an organized fashion towards the optic nerve head. These axons constitute the retinal nerve fibre layer (RNFL) or the *stratum opticum*. The fibres are non-myelinated, normally being invested with myelin only after passing through the lamina cribrosa. They follow a regular topographic course—the papillomacular bundle running between the macula and the optic disc, arcuate fibres from the temporal retina, and straight fibres from the nasal retina. The horizontal raphe separates the superior and inferior hemispheres.

Optical coherence tomography (OCT) is a non-invasive, quick and highly reproducible imaging modality. It is based on the principle of Michelson's interferometry, wherein the interference (constructive or destructive) between an incident ray of light passing through a structure and its reflection can be used to calculate its optical density. As neighbouring structures and interfaces differ in their optical density and reflectance properties, OCT provides information in the form of a 'slice' of tissues, just like an *in vivo* histology section. This information is colour-coded, with hot colours representing areas of high reflectance and cool colours representing areas of low reflectance. Various layers of the retina can thus be discerned. The thickness of each layer can be measured.

RNFL measurements have been principally used in the diagnosis of 'pre-perimetric' glaucoma. Peripapillary RNFL thinning may occur even prior to visual field defects being found using conventional white-on-white perimetry.

However, the RNFL can be affected by disease processes other than glaucoma. Anterograde degeneration occurs in pathologies earlier in the visual pathway, namely those affecting the pigment epithelium and photoreceptors. Retrograde degeneration may be caused by diseases of the central nervous system such as multiple sclerosis. The common end-result is a reduction in the thickness of the nerve fibre layer. Disease-specific patterns of RNFL loss may also be observed.

## RNFL OCT BY DIFFERENT DEVICES

Time domain-optical coherence tomography (TD-OCT) has been used commonly in clinical practice, producing a large inventory of circular scan data for RNFL assessment. Spectral domain (SD)-OCT produces three-dimensional (3D) data volumes.

Direct comparisons of RNFL thickness measurements of OCT instruments may be misleading, as there are considerable differences among the devices.<sup>1</sup> Physicians should consider this fact before judging a change in the

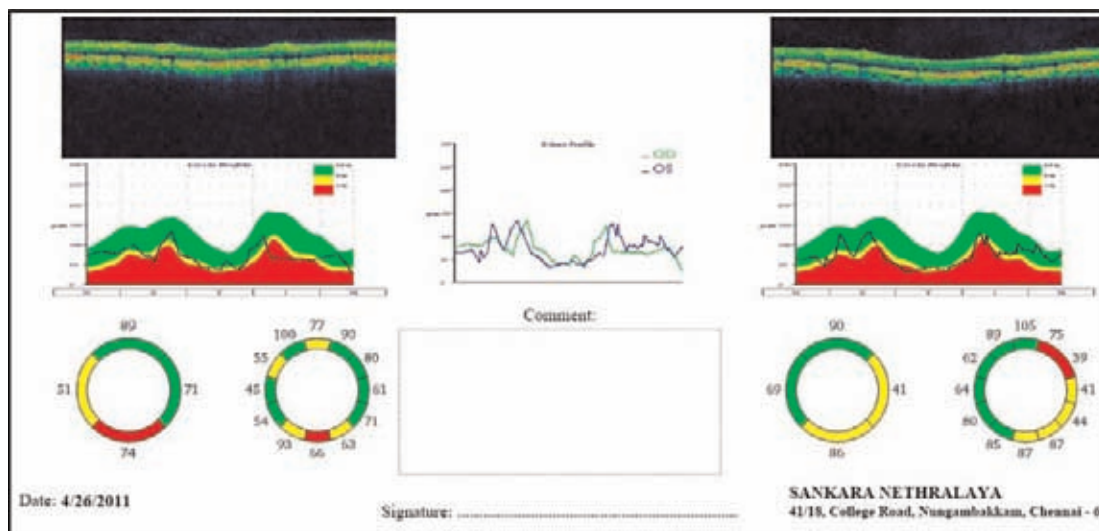


Figure 1. RNFL OCT of both eyes of a patient with toxic optic neuropathy. The false colour OCT scan is shown at the top and the 'unravalled' circular scan data, showing the RNFL thickness graph plotted against colour-coded probability zones, are given at bottom of the scan; the quadrant and clock-hour thickness displays are shown at the bottom; and the binocular thickness graph for inter-eye comparison is shown at the centre.

RNFL thicknesses if they were measured using different OCT devices.<sup>2</sup> Scan location matching may provide follow-up comparability between TD-OCT circular scan data and 3D SD-OCT scan data.<sup>3</sup>

## RNFL MEASUREMENTS IN SPECIFIC DISEASE ENTITIES

### Multiple sclerosis

RNFL measurements in patients with multiple sclerosis (MS) were found to be heterogeneous and varied from normal to showing marked thinning.<sup>4,5</sup> Thinning of the RNFL correlates with the number of episodes of prior optic neuritis, disease duration, and MS subtype (most significant reductions occurring in primary and secondary progressive subtypes).<sup>6,7</sup>

RNFL thinning in MS can occur in two settings. Focal, gross areas of thinning are observed after optic neuritis.<sup>8-10</sup> More subtle, global and progressive thinning seems to be related to the disease process itself.<sup>11</sup> This progressive rarefaction may be beyond the resolution limits of even advanced SD-OCT techniques.<sup>10,11</sup>

RNFL measurements were thought to be a possible tool for monitoring disease progression in MS. However, there are drawbacks to this approach.<sup>12</sup>

Firstly, it is unknown whether diffuse RNFL loss occurs in all patients with MS (or only in certain subtypes). Doubts also exist as to why and whether a diffuse CNS disease such as MS would actually produce a retrograde trans-synaptic degeneration of the RNFL.

Additionally, the range of 'normal' RNFL thickness values is large, 75–125  $\mu\text{m}$ , with a mean of  $97.2 \pm 9.7 \mu\text{m}$ .<sup>11</sup> Hence, it is difficult to draw any conclusions from a single RNFL reading. Serial RNFL measurements will be needed to detect progressive thinning, with a minimum observation period of at least 2 years being suggested in MS patients without optic neuritis.<sup>13</sup> A global RNFL reduction of about 2–4  $\mu\text{m}$  per year was suggested in MS patients without optic neuritis.<sup>6,13</sup>

Progressive thinning must be differentiated from 'physiological' RNFL thinning due to age.<sup>11</sup>

Lastly, RNFL measurements need to be performed under essentially the same conditions and need special testing algorithms to ensure comparability across machines and technologies (time domain vs. spectral domain).

A study with the longest follow-up (2 years)<sup>12</sup> in a well-defined cohort of relapsing–remitting (RRMS) and secondary–progressive (SPMS) forms without optic neuritis in the preceding 12 months did not find a significant RNFL reduction. It suggested that OCT as yet cannot replace MRI or even serve as a new surrogate marker in MS.

A recent study done in patients with longitudinally extensive transverse myelitis found localized RNFL loss even in the absence of previous episodes of optic neuritis, suggesting subclinical optic nerve damage in these patients.<sup>14</sup>

### Toxic optic neuropathies

A recent report of RNFL measurements in tobacco–alcohol-induced toxic optic neuropathy demonstrated

thinning in the temporal quadrant in two patients. In one patient, however, there was a thickening of the RNFL, which led the authors to suggest the presence of RNFL oedema, a finding reported earlier.<sup>15</sup> All patients had bilateral central or centrocaecal scotoma on perimetric testing.

Similarly, OCT has been used in the evaluation of patients on ethambutol. Findings vary with the duration of exposure, with the thickening of the papillomacular bundle observed in the early stage<sup>16</sup> and thinning in the chronic stage.<sup>17</sup>

RNFL measurements may also be a useful objective surrogate marker in patients who are unable to perform visual field examination, for example, vigabatrin-associated optic neuropathy.<sup>18</sup>

### Traumatic optic neuropathy

The RNFL undergoes progressive thinning after trauma to the optic nerve. Thinning has been noted to continue up to 70 days after injury.<sup>19</sup> When compared with macular thickness, RNFL thickness shows greater and faster reductions in traumatic neuropathy.<sup>20</sup>

### Retinitis pigmentosa

Various studies in the past have shown a reduced number of ganglion cells in RP patient eyes compared with a control group.<sup>21</sup> Recent therapeutic modalities, such as gene therapy and retinal stem cell transplantation, are aimed at restoring or preserving photoreceptor functions. In patients with RP, these can be successful only if there is some preservation of inner retinal layers. These observations could have an impact on future treatment strategies and imply that patients considered for various treatment options would benefit by an evaluation of nerve fibre layer thickness.

One study done by a group showed that 40% of all participating RP patients had some thinning of the peripapillary RNFL as measured by OCT. RNFL thinning by OCT in RP patients may be present with a normal appearance of the optic disc on clinical examination. RNFL damage may also be present in patients without clinically significant loss of visual acuity.<sup>22</sup>

A subsequent study done by the same group using Fourier-domain OCT<sup>23</sup> also found thinning of the RNFL in about 40% of the eyes with RP. However, an abnormal increase in RNFL thickness was observed in 21.65% of the eyes. No association was found between the presence of CME and increased RNFL thickness.

Another recent study using Fourier-domain OCT showed the thickening of the RNFL in the majority of patients with RP and predictably reduced receptor layer thickness outside the central fovea.<sup>24</sup>

### Other chorioretinal dystrophies

Lim et al.<sup>25</sup> measured the thickness of the inner retinal (i.e., RGC, RNFL and inner plexiform) and outer retinal (i.e., inner nuclear, outer plexiform and receptor) layers in patients with retinal dystrophy. They reported that



patients with retinal dystrophy [retinitis pigmentosa (3), cone-rod degeneration (2), and Stargardt's disease (2)] had small decreases in the inner layers, as opposed to large decreases in the outer retinal layers, compared with seven normal controls.

A study in patients with choroideaemia showed RNFL thinning in the superior and inferior peripapillary quadrants and thickening in the temporal quadrant.<sup>26</sup>

### Hereditary optic neuropathy

Dominant optic atrophy has been linked to mutations in the OPA1 gene. A study of the RNFL thickness in 40 patients with DOA found a significant reduction in the average RNFL thickness in the OPA1 group compared with normal controls. There was a severe involvement of the temporal papillomacular bundle, with relative sparing of the nasal fibres. The rarefaction of the RNFL was greater in patients with the more severe disease phenotype (DOA+), which has additional neuromuscular features.<sup>27</sup>

### Amblyopia

SD-OCT performed in the eyes of patients with strabismic and anisometropic amblyopia, as well as in the eyes of a third control group with anisometropia without amblyopia, found that the mean RNFL thickness was similar in the amblyopic and the fellow eyes. Central macular thickness was, however, significantly higher in those eyes with anisometropic amblyopia than in the fellow eyes.<sup>28</sup>

### Diabetic retinopathy

Fluorescein angiography can differentiate retinal thickening into 'ischaemic' and 'non-ischaemic'. The Heidelberg Spectralis OCT was used to perform an in vivo morphometric analysis of areas of retinal thickening. Ischaemic areas were significantly thicker than non-ischaemic areas. This difference was due chiefly to thickening of the middle retinal layers (inner nuclear layer, outer plexiform layer and outer nuclear layer). The inner retinal layers (retinal nerve fibre layer, ganglion cell layer and inner plexiform layer) did not show a significant difference, while the outer layers (photoreceptors plus retinal pigment epithelium layer) were slightly thinner in ischaemic areas.<sup>29</sup>

### Neurodegenerative disease

Alzheimer's disease is a prototypical neurodegenerative disorder. Mild cognitive impairment (MCI) may represent an early stage of this disease. OCT measurements of the RNFL were performed in subjects with MCI, patients with Alzheimer's disease and age-matched normal controls. There was a significant decrease in the RNFL thickness in patients with both MCI and Alzheimer's disease compared with the controls. However, the difference between the MCI group and Alzheimer's group was not

significant, and there was no relation between RNFL thinning and the severity of dementia.<sup>30</sup>

## CONCLUSIONS

Measurement of the RNFL thickness provides a useful and objective method for diagnosing a subclinical disease as well as for detecting disease progression. It throws light on the natural history of diseases affecting the retina, the optic nerve and the central nervous system. Measurements using OCT are highly reproducible and accurate, with ever-improving resolution.

## REFERENCES

1. Lee ES, Kang SY, Choi EH, Kim JH, Kim NR, Seong GJ, Kim CY. Comparisons of nerve fiber layer thickness measurements between stratus, cirrus, and RTVue OCTs in healthy and glaucomatous eyes. *Optom Vis Sci.* 2011;88(6):751-758.
2. Hong S, Kim Y, Shim J, Kim CY, Seong GJ. Inter-device agreement of retinal nerve fiber layer thickness measurements using spectral domain cirrus HD OCT. *Kor J Ophthalmol* 2011;25(2):105-109.
3. Kim JS, Ishikawa H, Gabriele ML, Wollstein G, Bilonick RA, Kagemann L, Fujimoto JG, Schuman JS. Retinal nerve fiber layer thickness measurement comparability between time domain optical coherence tomography (OCT) and spectral domain OCT. *Invest Ophthalmol Vis Sci* 2010;2(1):896-902.
4. Henderson AP, Trip SA, Schlottmann PG, Altmann DR, Garway-Heath DF, et al. An investigation of the retinal nerve fibre layer in progressive multiple sclerosis using optical coherence tomography. *Brain* (2008);131:277-287.
5. Serbecic N, Aboul-Enein F, Beutelspacher SC, Graf M, Kircher K, et al. Heterogeneous pattern of retinal nerve fiber layer in multiple sclerosis. High resolution optical coherence tomography: potential and limitations. *PLoS One* 2010;5:e13877.
6. Talman LS, Bisker ER, Sackel DJ, Long DA, Jr., Galetta KM, et al. Longitudinal study of vision and retinal nerve fiber layer thickness in multiple sclerosis. *Ann Neurol* 2010;67:749-760.
7. Henderson AP, Trip SA, Schlottmann PG, Altmann DR, Garway-Heath DF, et al. A preliminary longitudinal study of the retinal nerve fiber layer in progressive multiple sclerosis. *J Neurol* 2010;257:1083-1091.
8. Serbecic N, Beutelspacher SC, Kircher K, Reitner A, Schmidt-Erfurth U. Interpretation of RNFLT values in multiple sclerosis-associated acute optic neuritis using high-resolution SD-OCT device. *Acta Ophthalmol.* doi:10.1111/j.1755-3768.2010.02013.x.
9. Serbecic N, Beutelspacher SC, Aboul-Enein FC, Kircher K, Reitner A, et al. Reproducibility of high-resolution optical coherence tomography measurements of the nerve fiber layer with the new Heidelberg Spectralis optical coherence tomography. *Br J Ophthalmol* 2010; doi:10.1136/bjo.2010.186221.
10. Khanifar AA, Parlitsis GJ, Ehrlich JR, Aaker GD, D'Amico DJ, et al. Retinal nerve fiber layer evaluation in multiple sclerosis with spectral domain optical coherence tomography. *Clin Ophthalmol* 2010;4:1007-1013.
11. Garcia-Martin E, Pueyo V, Ara J, Almarcegui C, Martin J, Pablo L, Dolz I, Sancho E, Fernandez F. Effect of optic neuritis on progressive axonal damage in multiple sclerosis patients. *Mult Scler* 2011. [Epub ahead of print].
12. Serbecic N, Aboul-Enein F, Beutelspacher SC, Vass C, Kristoferitsch W, et al. High resolution spectral domain optical coherence tomography (SD-OCT) in multiple sclerosis: the first follow up study over two years. *PLoS ONE* 2011;6(5):e19843. doi:10.1371/journal.pone.0019843.
13. Petzold A, de Boer JF, Schippling S, Vermersch P, Kardon R, et al. Optical coherence tomography in multiple sclerosis: a systematic review and meta-analysis. *Lancet Neurol* 2010;9:921-932.
14. Moura FC, Fernandes DB, Apóstolos-Pereira SL, Callegaro D, Marchiori PE, Monteiro ML. Optical coherence tomography evaluation of retinal nerve fiber layer in longitudinally extensive transverse myelitis. *Arq Neuropsiquiatr* 2011;69(1):69-73.

15. Kee C, Hwang J-M. Optical coherence tomography in a patient with tobacco-alcohol amblyopia. *Eye* 2008;22:469-470. doi:10.1038/sj.eye.6702821; published online 13 April 2007.
16. Kim U, Hwang JM. Early stage ethambutol optic neuropathy: retinal nerve fiber layer and optical coherence tomography. *Eur J Ophthalmol* 2009;19(3):466-469.
17. Zoumalan CI, Agarwal M, Sadun AA. Optical coherence tomography can measure axonal loss in patients with ethambutol-induced optic neuropathy. *Graefes Arch Clin Exp Ophthalmol*. 2005;243(5):410-416 [Epub ahead of print 2004 Nov 23].
18. Clayton LM, Dévilé M, Punte T, Kallis C, de Haan GJ, Sander JW, Acheson J, Sisodiya SM. Retinal nerve fiber layer thickness in Vigabatrin-exposed patients. *Ann Neurol* 2011;69(5):845-854. doi: 10.1002/ana.22266. [Epub ahead of print 2011 Jan 19].
19. Medeiros FA, Moura FC, Vessani RM, Susanna R, Jr. Axonal loss after traumatic optic neuropathy documented by optical coherence tomography. *Am J Ophthalmol* 2003;135(3):406-408.
20. Cunha LP, Costa-Cunha LV, Malta RF, Monteiro ML. Comparison between retinal nerve fiber layer and macular thickness measured with OCT detecting progressive axonal loss following traumatic optic neuropathy. *Arq Bras Oftalmol* 2009;72(5):622-625.
21. Stone JL, Barlow WE, Humayun MS, de Juan E, Jr, Milam AH. Morphometric analysis of macular photoreceptors and ganglion cells in retinas with retinitis pigmentosa. *Arch Ophthalmol* 1992;110:1634-1639.
22. Walia S, Fishman GA, Edward DP, Lindeman M. Retinal nerve fiber layer defects in RP patients. *Invest Ophthalmol Vis Sci* 2007;48(10):4748-4752.
23. Walia S, Fishman GA. Retinal nerve fiber layer analysis in RP patients using Fourier-domain OCT. *Invest Ophthalmol Vis Sci* 2008;49:3525-3528.
24. Hood DC, Lin CE, Lazow MA, Locke KG, Zhang X, Birch DG. Thickness of receptor and post-receptor retinal layers in patients with retinitis pigmentosa measured with frequency-domain optical coherence tomography. *Invest Ophthalmol Vis Sci* 2009;50:2328-2336.
25. Lim JI, Tan O, Fawzi AA, Hopkins JJ, Gil-Flamer JH, Huang D. A pilot study of fourier domain optical coherence tomography of retinal dystrophy patients. *Am J Ophthalmol* 2008;146(3):417-426.
26. Genead MA, McAnany JJ, Fishman GA. Retinal nerve fiber thickness measurements in choroideremia patients with spectral-domain optical coherence tomography. *Ophthalm Genet* 2011;32(2):101-106. [Epub 2011 Jan 26].
27. Yu-Wai-Man P, Bailie M, Atawan A, Chinnery PE, Griffiths PG. Pattern of retinal ganglion cell loss in dominant optic atrophy due to OPA1 mutations. *Eye (Lond)* 2011;25(5):596-602. [Epub 2011 Mar 4].
28. Al-Haddad CE, El Mollayess GM, Cherfan CG, Jaafar DF, Bashshur ZF. Retinal nerve fibre layer and macular thickness in amblyopia as measured by spectral-domain optical coherence tomography. *Br J Ophthalmol* 2011 Mar 11. [Epub ahead of print].
29. Reznicek L, Kernt M, Haritoglou C, Kampik A, Ulbig M, Neubauer AS. In vivo characterization of ischemic retina in diabetic retinopathy. *Clin Ophthalmol* 2010;5:31-35.
30. Kesler A, Vakhapova V, Korczyn AD, Naftaliev E, Neudorfer M. Retinal thickness in patients with mild cognitive impairment and Alzheimer's disease. *Clin Neurol Neurosurg* 2011 Mar 29. [Epub ahead of print].

---

## ANSWER FOR MUSCLE PUZZLE

Answer: SIXTH NERVE PALSY LEFT EYE

The differential diagnoses for monocular abduction deficit are sixth-nerve palsy, type 1 Duane's retraction syndrome, entrapment of medial rectus muscle after orbital trauma, Grave's ophthalmopathy and myasthenia gravis.

Diagnostic strabismus measurements for purposes of evaluating sixth-nerve palsy include those obtained in the preferred head posture, the forced primary position and the lateral gaze field. Forced duction test (FDT), forced generation test (FGT) and saccadic velocity analysis are performed to evaluate the muscle function. A characteristic "floating" saccade may be observed on clinical examination. A 40% or greater difference between saccadic velocities of agonist and antagonist muscles is diagnostic of a true palsy. Saccadic velocity analysis also serves to evaluate the improvement after surgical intervention. A clinical trial with botulinum toxin during the acute phase may distinguish paresis from a true palsy. The most common causes of sixth-nerve palsy in adults are vasculopathies due to hypertension, diabetes

or atherosclerosis, while in children, they are due to either trauma or neoplasia.

Sixth-nerve palsies should be left for many months to recover spontaneously during which time botulinum toxin may be used. Management of refractive errors and amblyopia is essential, especially in the case of congenital sixth-nerve palsy. Diplopia can be helped occasionally in partial palsies by prisms but usually by occlusion. Surgical intervention is recommended only for patients with persistent esotropia for at least 6 months.

For smaller deviations and where there is a significant residual muscle function, a recession-resection procedure may suffice. If the primary position deviation is larger than 35 pd, then a contralateral medial rectus recession may be performed. If there is marked incomitance, then contralateral medial rectus may be posteriorly fixated (Faden's). With very large deviations and where there is minimal or no residual sixth-nerve function, an injection of botulinum toxin into ipsilateral medial rectus plus horizontal transposition of vertical recti may be used.

---