

# insight

Vol. XXI No. 2

JULY 2003

Scientific Journal of  
**MEDICAL & VISION RESEARCH FOUNDATIONS**  
18, COLLEGE ROAD, CHENNAI - 600 006, INDIA

## Editorial

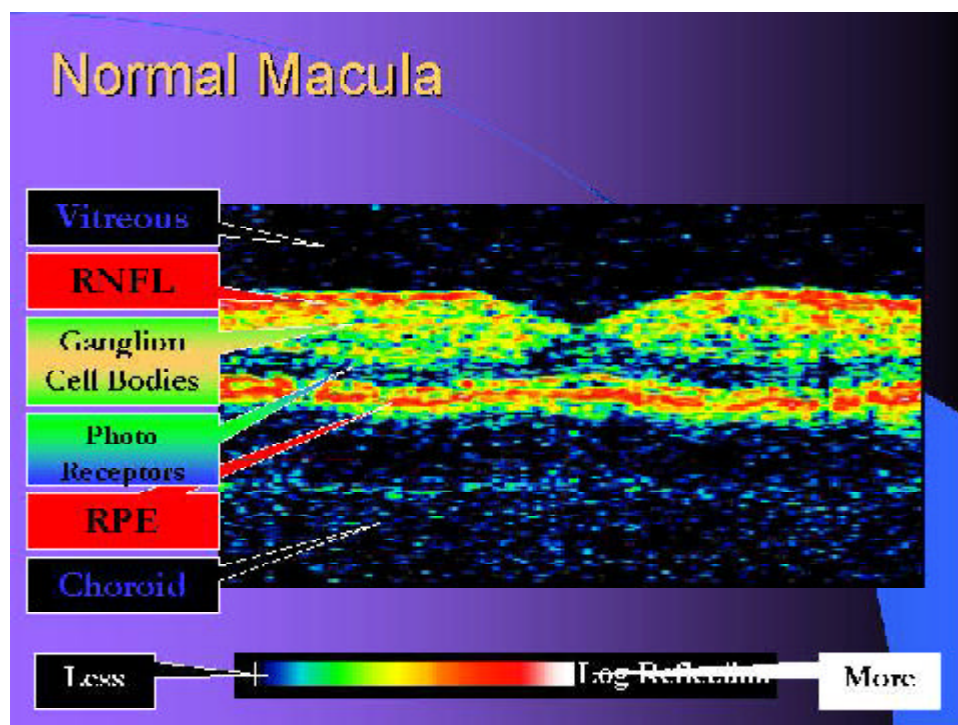
**Perspective — Intraocular lens power calculations after corneal refractive surgery**  
— *Srinivas K Rao*

**Diplopia management with Fresnel prisms - a clinical experience** — *Dharani R, Meenakshi S, Jayarajini S, Sumita Agarkar and Sujatha Guha*

**Needle Stick Injuries** — *A Mahalingam and P Suresh Kumar*

**MUSCLE PUZZLE** — *Aarti Kabra and S. Meenakshi*

**Last Page - Optical Coherence Tomography in Macular Disorders**  
— *Sachin Kabra and Pratik Ranjan Sen*



OCT picture of normal macula showing various layers of retina.

\_\_\_\_\_



\_\_\_\_\_

## EDITORIAL

Errors in DBR calculation can lead to disastrous results. This can lead to a situation that is difficult to explain away as a known complication and is one that is fraught with legal implications. The chances of such an error increases manifold in a patient who has undergone prior refractive surgery. Factors such as pre refractive surgery refractive error, error that has been corrected with the refractive surgery, current refractive status of the eye are all factors having an implication in DBR calculation of these patients. In addition, these patients are who had undergone refractive surgery in the first place to get rid of their glasses and are unlikely to be happy if made to wear thick lenses once again after cataract surgery. We have an article in the Perspective section of this issue of Insight addressing this very important issue.

Another area of concern for all medical professionals is the risk of being infected through a needle prick injury - something most of us would have brushed aside as innocuous in the pre HIV days. An interesting article in this issue gives us guidelines to prevent such an accident and also outlines what to do next if such an accident were to occur.

Despite the availability of multiple modes to image the fundus such as the indirect ophthalmoscope, fundus camera, fluorescein and indocyanine green angiograms, none could give us an in vivo histopathological section, that is until the OCT. The basics of the OCT, indications for its use in evaluation of fundus disorders are detailed in the last page of this issue.

Dr Mahesh P Shanmugam  
*Editor*

### **CME PROGRAMMES FOR THE SILVER JUBILEE YEAR 2003**

This Academic Year being the "Silver Jubilee Year" of Sankara Nethralaya attracts special significance and importance. Apart from the continuous efforts directed towards improvement of Patient's Care and Patient's Education on prevention and cure, the foundation has also lined up various CME Programmes for Ophthalmologists and Optometrists for updating their skill and knowledge.

<b>Sl.No.</b>	<b>Topics</b>	<b>Date</b>
1.	Vitreo-retina	24th, 25th & 26th July 2003
2.	Glaucoma	6th & 7th December 2003

The programmes are aimed to provide continuing medical education to the practising Ophthalmologists, Residents in Ophthalmology and to the Optometrists.

#### **FOR MORE DETAILS, PLEASE CONTACT**

**Mr. N. Sivakumar**

The Academic Officer — SANKARA NETHRALAYA  
18, College Road, CHENNAI – 600 006

Fax: 91-44-8254180 Email: [academic@sankaranethralaya.org](mailto:academic@sankaranethralaya.org)

## Perspective:

# Intraocular lens power calculations after corneal refractive surgery

Srinivas K Rao

Cataract surgery has evolved tremendously in the past few decades and is currently considered a refractive procedure with most patients expecting excellent unaided vision following the procedure. Present day techniques of phacoemulsification, which disturb the corneal contour minimally and ensure in-the-bag intraocular lens (IOL) placement in a consistent fashion, have contributed to such results. An improved understanding of the methods used for IOL power calculation and the precision of current technologies used to measure axial length and corneal curvature has also contributed to the increased accuracy of cataract surgery.

Another procedure, which has gained tremendous popularity in recent years, is excimer laser corneal refractive surgery and it is currently the second most commonly performed ocular surgical procedure. Although laser in situ keratomileusis (LASIK) is the most advocated procedure, a large number of patients have undergone photorefractive keratectomy (PRK) and radial keratotomy (RK) in the past. Most of these refractive procedures have been performed in patients in their second to fourth decades, and as these individuals age they will need cataract surgery as well. However, initial attempts resulted in poor refractive predictability following cataract surgery in these eyes. The purpose of this article is to highlight the reasons for such poor outcomes, and to review the methods described to overcome these problems.

## The problem

The two most important measurements that aid accurate IOL power calculation are the axial length of the eye and the corneal curvature. Their importance is highlighted by the fact that an error of 1 D in keratometry

would result in an equivalent error in IOL power, while a 0.33 mm error in axial length determination would cause a 1 D error in IOL power in an eye of average axial length. In eyes shorter than 22 mm, the magnitude of the error in IOL power estimation would increase.

In RK, deep incisions in the peripheral cornea allow the intraocular pressure to shift the peripheral cornea outwards, resulting in a flattening of the central corneal curvature. There is thus, no tissue removal in this procedure, unlike in PRK and LASIK, in which the excimer stromal ablation results in tissue removal from the central cornea. In the latter procedures, tissue removal would depend on the amount of myopic correction attempted. Based on a rule-of-thumb that 1 D of refractive correction requires the removal of 10  $\mu\text{m}$  of central corneal tissue, a 12 D correction would require the removal of about 120  $\mu\text{m}$  of corneal tissue. Since most authorities consider 12 D the upper limit for safe myopic refractive surgery, it is unlikely that greater tissue removal would be seen in most of these patients. Axial length measurement using non-contact ultrasound techniques and the IOL master, which uses the principle of optical coherence, would detect this amount of tissue loss, when measuring the axial length. Contact ultrasound techniques may not have the sensitivity to detect this change and hence may be a source of error in IOL power calculations. This should lead to a 0.3 to 0.5D error in IOL power estimation. Studies of IOL power calculation in eyes that have undergone corneal refractive surgery have however, indicated that most of the error that occurs results from inaccurate estimation of the corneal power.

Standard keratometry makes certain assumptions regarding corneal shape. The cornea is considered a regular spherocylindrical surface, and the measurement of its curvature is derived from points situated on a central circle which is about 3 mm in diameter. Since the central cornea within this zone is considered to be a spherical surface, this measurement is assumed to represent the power distribution within this area and at the corneal apex. Since keratometers use the reflection of a target from the anterior corneal surface, what is measured is the curvature of the anterior corneal surface. Refraction at the posterior corneal surface results in a negative power, and the overall power of the cornea is the algebraic sum of these two components. Since the posterior corneal power cannot be measured using standard keratometric techniques, manufacturers use a modification in the refractive index of the cornea to account for this factor. Hence, most keratometers use a corneal refractive index of 1.376 instead of the true value of 1.3375. This allows a conversion of the measured radius of curvature of the anterior surface to the total power of the cornea. For this assumption to be valid however, a constant relationship between the anterior and posterior corneal surfaces is assumed. This assumption is violated in excimer refractive surgery, in which tissue is removed from the anterior corneal surface. This would therefore, further affect the accuracy of conversion of the measured anterior radius of curvature into corneal power in such eyes.

Since the shape of the cornea after refractive surgery, be it RK or excimer surgery is oblate - meaning that there is a negative shape factor or central flattening, measurement of the paracentral cornea results in an erroneously steeper value for the central corneal power. This error is enhanced by the fact that the flat post-refractive surgery cornea reflects the target of the keratometer from a larger central area. Thus, after RK and excimer surgery for myopia, the measured corneal power in the 3 to 4 mm zone is steeper than that in the central cornea, which the patient

uses for image formation. This results in an underestimation of the IOL power and a postoperative hyperopic refractive error. This is the main source of error in eyes that have undergone RK. In PRK and LASIK, in addition to this error, the alteration in the relationship between the anterior and posterior corneal surfaces introduces a second error when corneal power is calculated from the measured radius of curvature.

### The solution(s)

**1. Corneal topography** - The explanation in the previous paragraph indicates why standard keratometry results in poor refractive outcomes after IOL implantation in eyes that have had corneal refractive surgery. Most of the currently available computerized videokeratography units provide color-coded maps of corneal power distribution. The basic principles adopted by the Placido-based devices remain very similar to those in manual keratometers. Hence they are subject to the inaccuracies described earlier. However, in post-RK eyes, some degree of accuracy can be attained by ignoring the simulated keratometry values provided by the machine (measured from a 3 mm zone), and deriving the value from the center of the zone of flattening indicated in the topographic map. This is more accurate since these devices use data from more points on the corneal surface, including the cornea within the 3 mm zone measured by the keratometer. This method would not however be useful in eyes that have had excimer surgery, due to the inaccuracy in conversion mentioned earlier.

**2. The History method** - This method derives the post-refractive surgery keratometric value from the pre- and post surgery refractive data of the patient. This can be explained with the help of an example,

Data	
Preoperative refraction	= - 8 D
Preoperative keratometry	= 44 D
Refractive correction attempted	= - 8 D
Post-LASIK refraction	= - 1 D

Calculations

Refractive error corrected = 7 D

Hence, post-LASIK keratometry  
= (44 - 7) = 37D

This method uses the post-treatment refractive error of the patient, prior to the development of the cataract. This is usually obtained one month after LASIK, when refractive stability has been attained. Since the change in refractive error is the direct result of the corneal alterations produced by the surgical procedure, it is logical to derive the final corneal power by subtracting the refractive change attained from the pre-treatment refractive error. Although this method works fairly well, it requires access to patient data in the pre- and early post-treatment periods. Details of the surgical procedure, including the correction attempted are also important.

**3. The Hard contact lens method** - In this technique, a hard contact lens of known base curve is placed on the eye with lens changes, and refraction is performed. The subjective refraction with the contact lens in place is compared with the refraction obtained without the contact lens. These values are used to derive the corneal power, using the following relationship,

Keratometry (D) = Contact lens base curve (D) + contact lens power (D) + (refraction with the contact lens) - (refraction without the contact lens)

The rationale of this method can be better explained with an example. If refraction without the contact lens (base curve 38 D) is - 5.0 D, and with the contact lens in place is plano, it means that the cornea underlying the lens is steeper than the contact lens by 5 D. Hence the corneal power would be contact lens power plus 5 D (assuming that the contact lens power was zero). Thus,

Keratometry  
= 38 + 0 + (0) - (- 5) = 38 + 5 = 43 D

This method is advantageous because it does not require access to patient data. However, it is accurate only if the cataract

allows refraction and the patient has a best-corrected visual acuity of at least 6/18 (to ensure that the refraction is accurate). If the cataract is very dense or total, and accurate refraction is not possible, or if the visual acuity in the cataractous eye cannot be improved beyond 6/24, then the accuracy of this method is open to question.

**4. Intraoperative retinoscopy** - In this technique, cataract surgery is completed and retinoscopy is performed intraoperatively in the aphakic eye. From the aphakic refraction, the IOL power can be determined. Alternatively, the IOL chosen can be implanted and then retinoscopy is performed, although IOL exchange would be necessary if there was a significant error. It would also be necessary to consider the loss of aseptic technique that may occur during this intraoperative maneuver. Lastly, this technique would be inappropriate in eyes that have had refractive surgery for hyperopia as even minor inaccuracies in the working distance during retinoscopy could result in serious errors in IOL power.

**5. The DBR method** - This is the most recently described method, and in this approach, preoperative patient data is essential. When the patient presents for refractive surgery, in addition to refraction and keratometry, the axial length is also measured and the IOL power required for emmetropia is calculated. Following refractive surgery, the stable refractive error prior to onset of cataract is determined and the change in refraction effected by the surgical procedure is calculated. This can be explained with the aid of the following example,

Data	
Preoperative refraction	= - 5.25 D
Preoperative keratometry	= 46.2 D
Axial length	= 25.0 mm
IOL power for emmetropia	= 16.8 D (A constant 118.0)
Refractive correction attempted	= - 5.25 D
Post-treatment refraction	= Plano

Since there has been a 5.25 D change in refraction at the spectacle plane following surgery (12 mm vertex distance), the IOL inside the eye should have its power increased by an equivalent amount, for the post-refractive surgery eye to attain emmetropia. It is also calculated that for every diopter of change in IOL power, only 0.7 D of change in refraction at the spectacle plane will be achieved.

#### Calculations

$$\begin{aligned} &5.25 \text{ D change at the spectacle plane} \\ &= 5.25 / 0.7 \\ &= 7.5 \text{ D change at the IOL plane} \\ \text{IOL power for emmetropia} \\ &= 16.8 \text{ D} + 7.5 \text{ D} = 24.3 \text{ D} \end{aligned}$$

This technique also requires access to pre- and post-operative patient data. Since this is a common requirement for many of the techniques described above, it is important for refractive surgeons to maintain detailed records. It may also be prudent to provide all patients undergoing refractive surgery with a copy of the relevant data, in case they approach another ophthalmologist for cataract surgery. Attention to the above details and adoption of the techniques described can

result in more accurate refractive outcomes following cataract surgery and IOL implantation, in patients who have had corneal refractive surgery.

#### References

1. Celikkol L, Pavlopoulos G, Weinstein B, Celikkol G, Feldman S. Calculation of intraocular lens power after radial keratotomy with computerized videokeratography. *Am J Ophthalmol* 1995; 120:739-50.
2. Holladay JT. Consultations in refractive surgery. *Refract Corneal Surg* 1989;5:203.
3. Hoffer KJ. Intraocular lens power calculation for eyes after refractive keratotomy. *J Refract Surg* 1995; 11:490-3.
4. Feiz V, Mannis MJ, Garcia-Ferrer F, Kandavel G, Darlington JK, Kim E, Caspar J, Wang JL, Wang W. Intraocular lens power calculation after laser in situ keratomileusis for myopia and hyperopia. *Cornea* 2001;20:792-7.
5. Seitz B, Langenbucher A. Intraocular lens power calculation in eyes after corneal refractive surgery. *J Refract Surg* 2000; 16:349-61.



## SANKARA NETHRALAYA CHENNAI



### SIR RATAN TATA TRUST COMMUNITY OPHTHALMOLOGY FELLOWSHIP PROGRAMME

**August / October / December 2003**

#### **CATARACT MICROSURGERY FELLOWSHIP (Basic & Advanced) - 2months duration.**

A registered Medical Practitioner with Post Graduate Diploma or Degree in Ophthalmology can apply.

#### **Bio Data**

Provide all useful information about yourself in plain paper and send it to the undersigned.

#### **Interview**

Candidates called for interview need to appear for MCQ / personal interview at their own cost. Rush application indicating the batch required. *For details write to :*

**Academic Officer**, MEDICAL RESEARCH FOUNDATION, 18, College Road,  
Chennai - 600 006. Fax : 044-28254180 e-mail : [academic@sankaranethralaya.org](mailto:academic@sankaranethralaya.org)

***Bio Data & Application can be faxed or e-mailed or sent by speed post.***

# Diplopia management with Fresnel prisms - a clinical experience

Dharani R, Meenakshi S, Jayarajini S, Sumita Agarkar and Sujatha Guha

Diplopia is one of the most troublesome visual symptoms that a patient can experience, as it interferes with the ability to perform any visual task. Ocular misalignment is the commonest cause of binocular diplopia.

Fresnel prisms are excellent option for non-surgical management of diplopia<sup>1-4</sup>. We present three cases of ocular misalignment leading to diplopia, which was relieved with Fresnel prisms.

## Case 1

An 18-year-old male reported with a history of blunt trauma in right eye with a visual acuity of 3/60 and <N36. The visual acuity was 6/6 and N6 in the left eye. Anterior segment was normal in both eyes, except for angle recession in superior and nasal quadrants in the right. Fundus examination showed a partial rhegmatogenous retinal detachment in right eye for which the patient underwent scleral buckling.

Post operatively, visual acuity improved to 6/12; N6 with myopic correction, but the patient was complaining of binocular diplopia. Extra ocular movements were full in both eyes. Alternate prism cover test revealed right exotropia of 45-prism dioptres. The patient underwent squint surgery following which there was a residual exotropia of 30-prism dioptres. This undercorrection may sometimes be seen in sensory strabismus. The patient was referred to Orthoptic clinic for trial of Fresnel prism.

On trial, diplopia was minimized with 20-prism dioptres. After adequate adaptation with prism for fusion in free space patient was fitted with 20-prism dioptres as Fresnel prism in right eye and was advised to come for a follow up after 3 months.

## Follow up

At 10 months follow-up, the patient was using Fresnel prism without any diplopia or eyestrain. On examination, his visual acuity was 6/18, N6 in right eye and 6/6, N6 in left eye. Cover test revealed exophoria for distance and orthophoria for near.

## Case 2

A 31-year-old male reported with a history of blunt trauma to the right eye with a visual acuity of perception of light with inaccurate projection. The visual acuity was 6/9 and N6 in the left eye. Anterior segment examination revealed traumatic rupture of lens, corneal tear and edema and hyphema in right eye and the patient underwent primary wound repair and lensectomy.

Post-operatively visual acuity improved to 6/24 with aphakic correction. The patient was fitted with semi soft contact lens, which improved visual acuity to 6/9. However patient was complaining of diplopia with contact lens. Extra ocular movements were full in both eyes. Alternate prism cover test revealed right exotropia of 20-prism dioptres and hypotropia of 2-prism dioptres this cause of which was sensory. Patient was referred to Orthoptic clinic for a trial of Fresnel prism.

On trial, diplopia was minimized with 15-prism dioptres base in. After adequate adaptation with prism for fusion in free space, patient was fitted with 15-prism dioptres base in as Fresnel prism in right eye and was advised to come for a follow up after 3 months.

## Follow up

At 3 months follow-up, the patient was using Fresnel prism without any difficulty. On examination, the visual acuity was 6/9 and N6 in right eye and 6/6 and N6 in left

eye. Cover test revealed exophoria for distance and orthophoria for near.

### Case 3

A 47-year old man reported with decreased vision in left eye. On examination the visual acuity was 6/9 and N8 in right eye and perception of light with inaccurate projection in left eye. Anterior segments were normal in both eyes. Fundus examination revealed partial rhegmatogenous retinal detachment in left eye. The patient underwent scleral buckling which was uneventful.

Post-operatively the visual acuity improved to 6/18 and N8 in left eye, but the patient complained of binocular diplopia for distance and near. Alternate prism cover test revealed left exotropia of 12-prism dioptres and hypotropia of 20-prism dioptres. The patient was referred to optometry clinic for prescription of Fresnel prism. On trial, the patient was able to fuse diplopic images with 10-prism dioptres base in and 15-prism dioptres base down. The patient was prescribed with 10-prism dioptres base in as ground in prism and 15-prism dioptres base up as Fresnel prism in left eye.

### Follow up

At 10 months follow up, the patient was successfully using the Fresnel prism for distance and was keen on Fresnel prism for near vision. On examination, the visual acuity was 6/9 and N8 in right eye and 6/18 and N6 in left eye. Prism bar cover test revealed orthophoria for distance and 10 prism dioptres of left hypotropia. The patient was prescribed with 10-prism dioptres base up for near.

### Discussion

Fresnel prisms are reasonable permanent treatment option for diplopia management when large prisms cannot be incorporated in spectacles. Fresnel prisms can be prescribed in sector, often referred to as sector application of Fresnel prism in cases of incomitant deviations, when the magnitude of deviation is expected to change with time<sup>5,6,7</sup>.

The major disadvantages are blurring of vision, decreased contrast sensitivity due to scattering of light, colored fringes, visibility of the grooves, discoloration and peeling of prism membrane<sup>7</sup> from the glasses. Contrast sensitivity function is reduced for all spatial frequencies, to a greater degree at higher spatial frequencies<sup>7</sup>.

The main advantages of Fresnel prisms are reduced weight (approximately 1mm thickness), large diameter (67 mm), which can fit into any frame shape and ease of application. Fresnel prisms produce substantially less horizontal and vertical magnification of objects and less curvature of vertical lines<sup>8</sup>. On comparison with conventional prisms, visually insignificant difference has been reported for asymmetric horizontal magnification and change of vertical magnification with horizontal angle<sup>8</sup>.

None of our patients complained of blurred vision since the Fresnel prism was fitted in front of the non-dominant eye, so that clear vision was maintained through the better eye. One patient (case 2) complained of scattering of light in outdoors and two patients (case 1 and case 3) complained of discoloration of prism membrane. One patient (case 2) reported that the grooves were noticeable by others. None of the patients complained of colored fringes or peeling of the prism membrane.

### Conclusion

Fresnel prisms can be considered as a short term or long-term treatment option for diplopia and are more successful in achieving single binocular vision in cases where surgery may not be beneficial.

### References

1. M Flanders, N Sarkis. *Fresnel membrane prisms: clinical experience. Can J Ophthalmol* 1999; 34: 335-40.
2. S M Brown. *Fresnel prism treatment of sensory exotropia with restoration of sensory and motor fusion. J Cataract Refract Surg* 1999; 25: 441-443.



3. J Wylie, M Henderson et al., Persistent binocular diplopia following cataract surgery: etiology and management. *Eye* 1994; 8 (5): 543-6.
4. D A Bader. Fresnel prism for constant diplopia. *Am J Optom Physiol Opt* 1983 ; 60 (5): 410-1.
5. J M Sinelli, M X Repka. Prism treatment of incomitant horizontal deviations. *Am Orthopt J.* 1996; 46: 123-26.
6. B J Kushner. Management of diplopia limited to down gaze. *Arch Ophthalmol.* 1995; 113 (11): 1426-30.
7. Cotter S A, Frantz K A. Practical considerations in prism implementation. Cotter S A and London R (ed): *In Clinical uses of prism 1st ed.* St. Louis: Mosby; 1995: 64-71.
8. A J Adams, R J Kapash and E Barkan. Optical performance and optical properties of Fresnel membrane prisms. *Am J Optom Arch Am Acad Optom* 1971; 48: 289-297.

## ANAPPEAL

A lot of things in this world depend on money - security, shelter, education and even health. But at Nethralaya, money has ceased to be a pre-requisite for sight. Day after day, year after year, Nethralaya treats hundreds of patients absolutely free of cost and gives them back their sight. Treatment is provided free of cost to all patients with a monthly income below Rs.1,750/-.

Yet there is no discrimination between the free patient and the one who pays. Apart from the treatment, food, medicines and travel expenses are absolutely free.

Those free patients depend on Nethralaya, and Nethralaya depends on you.

So, come and join the **OPHTHALMIC MISSION TRUST**.

For questions about tax exempt status and contributions, please contact:

**Mr S V Acharya,**

*Treasurer*

Ophthalmic Mission Trust Inc. (OM Trust)

14613, Pommel Drive, Rockville,

MD 20850, U.S.A.

Phone: (301)251 0378

INTERNET e-mail : omtrustusa@hotmail.com

www.omtrust.org

For those of you in India and elsewhere, please contact:

**Dr S S Badrinath,**

*President & Chairman*

Sankara Nethralaya

(UNIT OF MEDICAL RESEARCH FOUNDATION)

18 College Road, Chennai 600 006

Phone: 826 1265, 827 1616

Fax: (044) 825 4180, 821 0117

INTERNET e-mail : chairman@sankaranethralaya.org

LOOK US UP ON THE WEB at <http://www.sankaranethralaya.org>

<http://www.omtrust.org>

GIVE ONLINE @ [www.icicicommunities.org](http://www.icicicommunities.org)

**COME, GIVE THE GIFT OF SIGHT**

# Needle Stick Injuries

A Mahalingam and P Suresh Kumar

## **Introduction:**

Needle stick injuries are wounds caused by needles that accidentally puncture the skin. Needle stick injuries are a hazard for people who work with hypodermic syringes and other needle equipment. These injuries can occur at any time when people use, disassemble, or dispose needles. When not disposed properly, needles can become concealed in linen or garbage and injure other workers who encounter them unexpectedly. A needle stick injury can be a devastating event. Although the risk of contracting blood-borne pathogen is low, the psychological trauma that follows the injury can be disabling in certain situations.

## **Hazards of Needlestick Injuries**

Accidental punctures by contaminated needles can inject hazardous fluids into the body through skin. There is potential for injection of hazardous drugs, but injection of infectious fluids, especially blood, is by far the greatest concern. Even small amounts of infectious fluid can spread certain diseases effectively. The pathogens that pose the most serious health risks are

- Hepatitis B virus (HBV)
- Hepatitis C virus (HCV)
- Human immuno deficiency virus (HIV)

Needle stick injuries have transmitted many other diseases involving viruses, bacteria, fungi, and other microorganisms to health care workers and laboratory researchers in rare, isolated events.

## **How Do Needlestick Injuries Occur?**

Several studies show that needles cause injuries at every stage of their use, disassembly, or disposal. But there is disagreement as to why the accidents are so common among health care workers or why simple solutions fail to solve the problem.

Nursing and laboratory staff usually experience 30 to 50 percent of all injuries during clinical procedures. Equipment design, nature of the procedure, condition of work, staff experience, recapping, and disposal has all been mentioned as factors that influence this occurrence.

## **1. Equipment Design:**

Safer innovative devices using protected needle devices or needle-free systems with self-sealing ports would alleviate many of these injuries. There is accumulating evidence suggesting that syringes with safety features reduce needle stick injuries.

## **2. Nature of Procedure:**

- while withdrawing a needle from an uncooperative patient
- a needle out of the rubber stopper of a vacuum tube which can jab the hand in a rebound reflex

Injuries commonly occur when workers try to do several things at the same time, especially while disassembling or disposing off needles.

## **3. Conditions of Work:**

Work conditions that might contribute to an increase in the number of needle stick injuries include:

- staff reductions where nurses, laboratory personnel and students assume additional duties
- difficult patient care situations in emergency conditions
- working at night with reduced lighting.

## **4. Staff Experience:**

New staff or students tend to have more needle stick injuries than experienced staff.

## **5. Recapping:**

Recapping can account for 25 to 30 percent of all needle stick injuries of nursing and laboratory staff. Often, it is the single most common cause. It is extremely dangerous to hold a needle in one hand and attempt to cover it with a small cap held in the other hand. Injuries occur three different ways:

- the needle misses the cap and accidentally enters the hand holding it
- the needle pierces the cap and enters the hand holding it
- the poorly fitting cap slips off of a recapped needle and the needle stabs the hand.

## **6. Improper Disposal:**

Virtually all needle stick injuries of domestic and conservancy staff are from needles that have either been lost in the workplace or thrown into regular garbage. Janitors and garbage handlers can also experience needle stick injuries or cuts from “sharps” when handling trash that contains needles or scalpels. This can be attributed to forgetfulness or lack of motivation or training on the part of people who work with and dispose off needles. Inconvenient disposal systems also contribute to these incidents. Maintenance staffs have also experienced needle stick injuries when they clean ducts or other areas with their hands and find hidden needles and syringes. These injuries usually happen when the maintenance staffs reach into areas they cannot see and are not wearing leather gloves.

### **How to Prevent Needlestick Injuries?**

Preventing needle stick injuries is the most effective way to protect workers from the infectious diseases that needle stick accidents transmit. A comprehensive needle stick injury prevention program would include:

#### **1. Employee Training & Education:**

Proper education of employees about the

importance of following universal precautions, using disposal methods, including recommended disposal containers, prompt emptying of disposal containers before they overflow and using preventive devices are essential elements of a program to minimize the needle stick injuries. Specifically, the training programs should address:

- risk of injury
- potential hazards
- recommended precautions for use and disposal of needles
- procedures for reporting injuries
- the importance of hepatitis B vaccination where appropriate.

The effectiveness of the training should be assessed on their understanding and knowledge, observing actual practice and monitoring the frequency of incidents.

#### **2. Recommended Guidelines:**

The following guidelines deal specifically with needle safety:

- needles, scalpel blades and other sharp instruments- workers should consider these as potentially infectious and handle them with care to prevent accidental injuries
- disposable needles and syringes, scalpel blades, and other sharp items- workers should place these in puncture-resistant containers located near the area of use. They should avoid overfilling the containers because accidental needle stick injuries may occur
- recapping- workers should not recap needles by hand or purposely bend, break, or remove them from disposable syringes or otherwise manipulate them by hand.

#### **3. Safe Recapping Procedures:**

In situations where recapping is considered necessary, safe approaches should be followed. Workers should never move an

exposed needle tip towards an unprotected hand.

#### **a. Single-Handed Scooping**

Recapping can be safe when people lay the cap on a flat surface and scoop it onto the tip of a syringe held in one hand. They must keep the free hand away from the sheath and well behind the exposed needle.

#### **b. Recapping Devices**

Several devices are available for recapping needles safely. Some devices permit single-handed recapping by parking a needle cap on a flat surface. Other devices are designed to protect the hand that holds the cap during two-handed recapping procedures.

### **4. Effective Disposal Systems:**

An effective system for disposing off used needles is crucial to preventing needle stick injuries. Having disposal containers readily available can greatly reduce the concern for recapping needles. Workers should place needles in wide-mouth, puncture-proof containers. Locating disposal containers specifically where needles have to be disposed safely without recapping and replacing the containers before they are completely filled and making sure that the containers are sealed, collected, and disposed of in accordance with local regulations for biomedical waste would be an ideal way of disposing off used needles. All staff should report every incident in which they find needles left at the bedside or thrown into the regular garbage. Through careful selection of sharps disposal products, (access design, size, etc.), their appropriate placement within all healthcare settings, and with certain safe disposal practices for Health Care Workers and facilities, risk of sharps injury can be reduced. The risk of needle sticks can be reduced by using new sharps waste treatment technologies near the point of use, or sharps collection followed by treatment in an on-site non-incineration

technology, or sharps collection and transport to an off-site treatment facility.

### **5. Safer Needle Devices:**

Safer needle devices have built-in safety control devices, such as those that use a self-sheathing needle, to help prevent injuries before, during, and after use through safer design features. There are different types of safety features that are available for safer needle devices such as:

- Passive safety features: remain in effect before, during and after use.
- Active devices: require the worker to activate the safety mechanism.
- Integrated safety design: have a safety feature that is built in as an integral part of the device and cannot be removed. This design feature is usually preferred.
- Accessory safety devices: have safety features that are external to the device and must be carried to, or be temporarily or permanently fixed to, the point of use. This design is dependent on employee compliance and according to some researchers, is less desirable.

Desirable Characteristics of Safety Devices should include:

- The device is needle less.
- The safety feature is an integral part of the device.
- The device is easy to use and practical.
- The device performs reliably.
- The safety feature cannot be deactivated and remains protective through disposal.
- The devices work effectively and reliably, and are acceptable to the health care worker, and do not adversely affect patient care.

#### **The immediate measures to be taken after an occupational exposure are as follows:**

- Use soap and water to wash any wound or skin site that came into contact with

infected blood or fluid.

- Flush exposed mucous membranes with water.
- Irrigate an open wound with sterile saline or disinfected infection.
- Eyes should be irrigated with clear water, saline or sterile eye irrigates.
- Report to the concern authority
- Counseling
- Use antiretroviral therapy in case of HIV needle stick injuries

#### **Post-exposure prophylaxis in HIV needle stick injuries**

- The term “Post-exposure prophylaxis” (PEP) refers to the treatment of occupational exposures using anti-retroviral therapy. The rationale is that antiretroviral treatment, which is started immediately after exposure to HIV, may prevent HIV infection.

#### **Current guidelines for PEP**

The currently recommended guidelines state that

- Therapy should be recommended after exposure.
- All regimens must include zidovudine.
- Therapy should be initiated within one to two hours of exposure.
- If the source patient's HIV status is unknown, decision to give PEP should be taken on a case-to-case basis.
- Follow-up counseling and HIV testing should be carried out periodically for at least 6 months (i.e. at baseline, 6 weeks, 12 weeks and 6 months). It is estimated that 95% of health care workers seroconvert within 6 months of exposure.

#### **Efficacy of PEP regimens**

Studies conducted in animals and in humans prove the efficacy of PEP regimens. Zidovudine has been the most widely studied agent for prophylaxis. A retrospective study of health care workers who used zidovudine

as PEP found that the risk of HIV infection was reduced by approximately 81%. Although the efficacy of combination regimens for PEP is unknown, combination drug regimens are currently recommended for PEP. This is because they are more potent and may be more effective against drug-resistant strains.

#### **Possible side effects of PEP**

Information about the toxicity of antiretroviral drugs in persons without HIV infection is limited. Health care workers who are given PEP need to be monitored for drug toxicity at baseline (on starting PEP), and two weeks after therapy begins. They should be advised to report acute illness and symptoms such as back or abdominal pain, pain or urination, blood in the urine, increased thirst and frequent urination. If these symptoms are reported, they must be evaluated immediately.

Nausea and diarrhoea often occur during the course of treatment. Prescribing antimotility and/or antiemetic agents or other medications for specific symptoms may enable the exposed health care worker to complete PEP without changing the regimen.

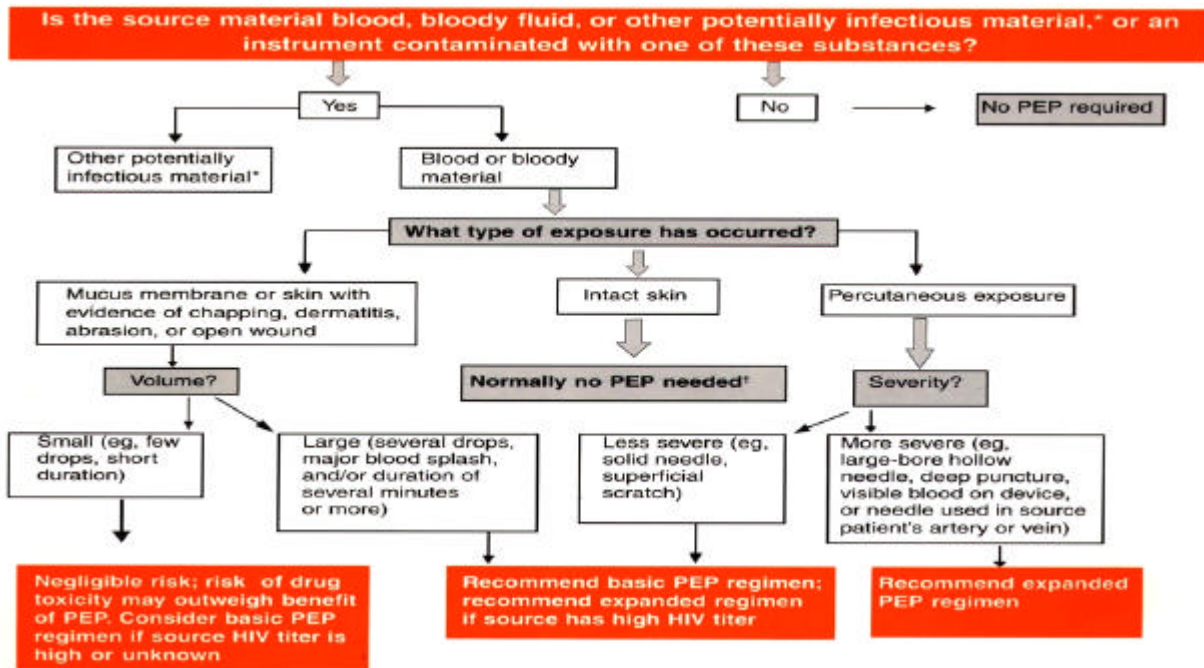
#### **What additional advice should the exposed health care worker be given?**

Exposed health care worker should avoid behaviors that carry a risk of secondary transmission of HIV for the duration of the follow-up period. This is especially true for the first 6 to 12 weeks after exposure, when seroconversion is most likely to occur:

The exposed health care worker should be advised on the following:

- Sexual abstinence
- Use of condoms to prevent sexual transmission and pregnancy
- Not to donate blood, plasma, organs, tissue or semen
- HIV and some drugs used in therapy can pass through breast milk. Consider discontinuing breast-feeding, particularly after high-risk exposures.

## Basic and expanded post exposure prophylaxis regimens



### CONCLUSIONS

Needle stick injuries are an important and continuing cause of exposure to serious and fatal diseases among health care workers. Greater collaborative efforts by all team members are needed to prevent needle stick injuries and the tragic consequences that can result. Such efforts are best accomplished through a comprehensive program that addresses institutional, behavioral and device related factors that contribute to the occurrence of needle stick injuries in health care team. Critical to the effort are the elimination of needle bearing devices where safe & effective alternative are available and the development, evaluation and use of needle devices with safety features.

### Suggested Reading:

1. Biswas J, *Ocular Lesions in AIDS In India*, (1st ed), Sankara Nethralaya, Chennai, 2001:42-49

2. William Sharney, *Hand book of Modern Hospital Safety*, Lewis publishers, USA 1999: 253-378.
3. Edwards C R W, Bouchier I A D, Haslett C, Chilvers E R, *Davidson's Principles & Practice of Medicine*, 17th Edition, Churchill Livingstone, UK 1995 : 89.
4. David Greenwood, Richard C B Slack, John Forrest Peutherer, *Medical Microbiology*, 14th Edition, Churchill Livingstone, UK, 1992:637-38.

### Suggested Browsing:

1. <http://www.australianprescriber.com>
2. <http://www.ofaaa.bc.ca>
3. <http://www.lambtonhealth.on.ca>
4. <http://www.cdc.gov>
5. <http://www.medscape.com>

# MUSCLE PUZZLE

Aarti Kabra and S. Meenakshi

**Patient no: 1: (figure 1a, 1b, 1c, 1d )**

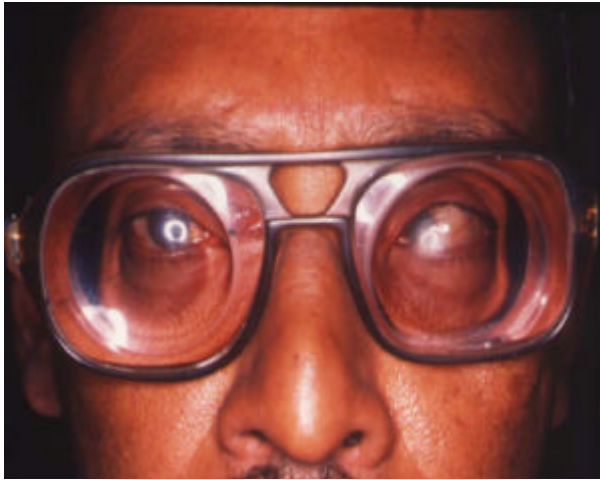

Fig.1a

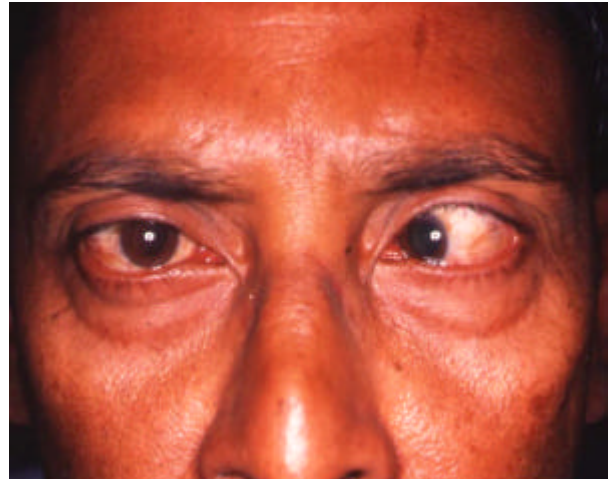

Fig.1b

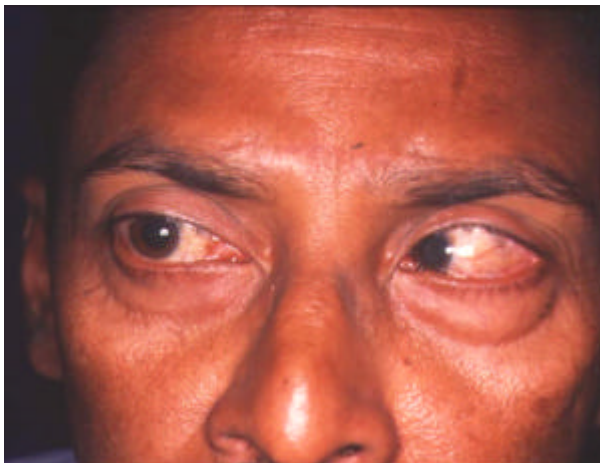

Fig.1c

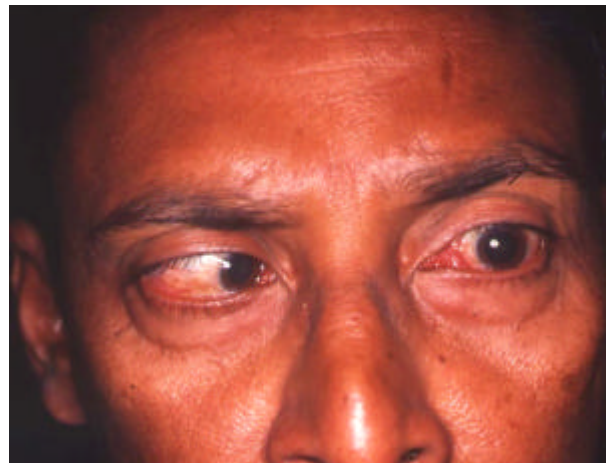

Fig.1d

This is a 42 year old patient presenting with progressive inward turning of left eye  
H/O Scleral Buckling in left eye 10 yrs back.

Vision: OD: 6/24, N6  
OS: HMCF, < N36

Refraction: OD: - 21.00 DS  
OS: - 22.00 DS/ -1.00 DC @ 90

Ocular motility : 30 LET (Hirschberg's test) with bilateral abduction deficit

**Patient no: 2: (figure 2a, 2b, 2c, 2d )**

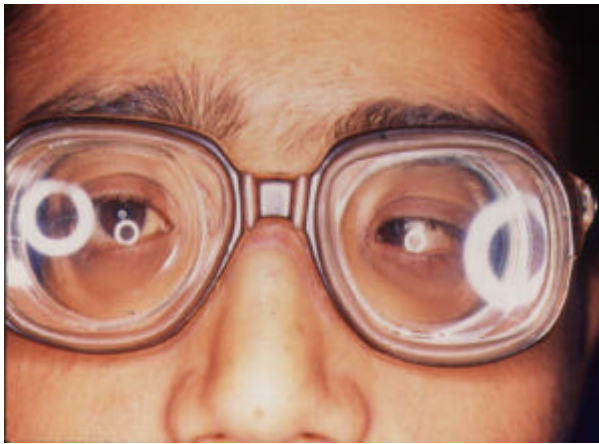


Fig.2a

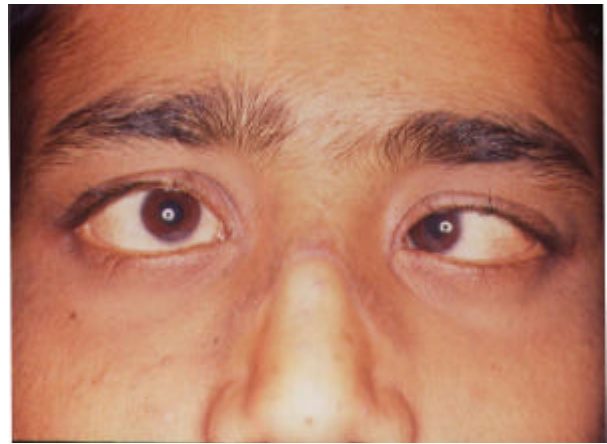

Fig.2b

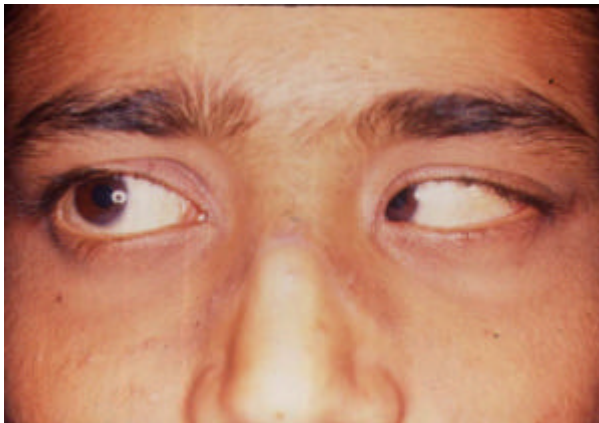

Fig.2c

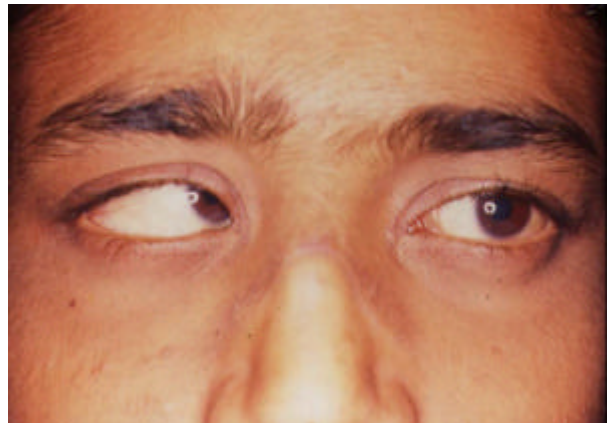

Fig.2d

This is a 17 year old patient presenting with gradually progressive inward deviation of right eye since past 11 yrs.

Vision: OD: 2/60, 6/18 RS

OS: 6/36, 6/6 RS

Refraction: OD: - 26.00 DS

OS: - 25.00 DS

Ocular motility : > 60 RET (Hirschberg's test) with bilateral abduction deficit

**Question : What is common to these two cases?**

**What is the diagnosis?**

Answers: Turn to page 42



# GLAUCOMA 2003 UPDATE

Dear Colleagues,

Cutting edge research in glaucoma has produced a plethora of new diagnostic techniques and therapeutic options. One question about this bewildering assortment of tests and drugs is their relevance to clinical practice. We have national and international experts with experience in these fields to put things in perspective at our CME programme on 6th and 7th December 2003.

We invite you to block your calendar this December and join us in Chennai for an update.

**Dr B Shantha**, *Organising Secretary*

## FACULTY

### International

Dr Ivan Goldberg (Australia)  
Dr Jost B Jonas (Germany)  
Dr Michal Schwartz (Israel)  
Dr Steve Seah & Team (Singapore)

### National

Dr G Chandra Shekar (Hyderabad)  
Dr Pradeep Vyas (Jalna)  
Dr Prafulla Sarma (Guwahati)  
Dr Ramanjit Sihota (New Delhi)  
Dr S Ramakrishnan (Tirunelveli)  
Dr Vinay Nangia (Nagpur)

### SN Faculty

## HIGHLIGHTS

**Newer imaging tools - Where to use them?**

**Newer medications – How do we use them?**

**Neuroprotection – Is it here?**

**Angle Closure glaucoma – What is new?**

**Case discussions**

**Symposium on Epidemiology**

**Posters from participants**

**Note:** Abstracts for poster presentations in the CME may be sent by email in the following format :

Title, Aim, Methods, Results and Conclusion (150 words).

**Last date 31 -10 - 2003.**

## Registration fee details

Delegates	– Rs 1500/-
#PGs	– Rs 750/-
Foreign delegates	– US \$100

**Last Date for Registration :  
31-10-2003**

## Late fee for Registration

Delegates	– Rs 2000/-
#PGs	– Rs 1000/-

@ Registration forms are available on line for print at

[www.sankaranethralaya.org](http://www.sankaranethralaya.org) and  
[www..ekalavya.org](http://www..ekalavya.org)

# PGs need to send proof of postgraduate status

## Mailing address :

**Dr B Shantha**

Medical Research Foundation

18, College Road,  
Chennai, TamilNadu

Phone:28271616 Ext. 1434

Fax:044-28254180

email: [drbs@sankaranethralaya.org](mailto:drbs@sankaranethralaya.org)

Web: <http://www.sankaranethralaya.org>,

<http://www.ekalavya.org>

**ANSWER: Esotropia and high myopia with abduction deficit**

**Fig. 1a, Fig. 2a: Patient is wearing high minus glasses**

**Fig. 1b, Fig. 2b: Primary gaze showing large esotropia**

**Fig. 1c, Fig. 2c: Right gaze - limitation of abduction in the right eye**

**Fig. 1d, Fig. 2d: Left gaze - limitation of abduction in the left eye**

## Esotropia in High Myopia

Esotropia has been described in association with high myopia. It can present in various forms. It can be comitant or incomitant.

- 1) Acquired Strabismus fixus has been described in conjunction with high myopia.<sup>1</sup>

The postulated theory suggests that there is fibrosis of the medial rectus muscle secondary to lateral rectus paralysis. The involved eye is fixed in the adducted position and cannot be moved. This can reach extreme form in which the cornea also is not seen in the palpebral fissure. Forced Duction Test helps in diagnosis.

### **Management:**

Complete disinsertion of the medial rectus muscle(s) along with resection of the lateral rectus muscle and recession of the conjunctiva and the Tenon's capsule.

- 2) Another form of strabismus with high myopia is the **Heavy eye syndrome**, which consists of a slow progressive development of esotropia and hypotropia.<sup>2</sup> Downward displacement of the lateral rectus has been noted in these eyes. It is thought to be due to scleral ectasia, which causes a downslip of the muscle in relation to the globe. This causes a depressing effect. This can be confirmed by MRI scan.<sup>3</sup>

### **Management:**

Supratransposition of the resected lateral rectus muscle along with recession of

medial rectus muscle has been described. This can be augmented with scleral fixation of the transposed muscle with silicon loop.<sup>4</sup> But the results are not satisfying.

- 3) Progressive strabismus in the form of restrictive motility disturbances has been described in high myopia. Various causes speculated include:

1. Disproportion between the size of the orbit and the enlarged or elongated myopic globe and contact between the elongated globes and the orbital walls and apices of the orbit.<sup>5</sup>
2. Compression of the lateral rectus against the lateral orbital wall by an enlarged globe.
3. Progressive fibrosis, myopathy, or myositis

- 4) **Acute Acquired Comitant Esotropia**<sup>6</sup> has also been described with myopia. This is called as the Bielschowsky type and is associated with high myopia and constant deviation both for distance and near. These patients usually begin with a small angle and gradually progress to a large deviation. However there is no evidence of lateral rectus paralysis. Some of these cases may demand neuroimaging to rule out any intracranial pathology.

Theories proposed for this type are:

1. Increased tone of medial rectus muscle
2. Direct damage to the lateral rectus muscle.

**Management:**

Surgery is usually effective in re-establishing good binocular function.

**References:**

1. Prakash P, Gupta NK, Menon V, Chandra M: *Myopic strabismus fixus convergens*. *Indian J Ophthalmol* 1989; 37: 24 - 26.
2. Aydin P, Kansu T, Sanac AS: *High myopia causing bilateral abduction deficiency*. *J Clin Neuro Ophthalmol* 1992; 12: 163 - 165.
3. Krzizok T, Kaufmann H, Traupe H: *Elucidation of restrictive motility in high myopia by magnetic resonance imaging*. *Arch Ophthalmol* 1997; 115: 1019 - 1027.
4. Krzizok T, Kaufmann H, Traupe H: *Newer approach to strabismus surgery in high myopia*. *Br. J Ophthalmol* 1997; 81: 625 - 630.
5. Demer JL, Noorden Von GK: *High myopia as an unusual cause of restrictive motility disturbance*. *Surv Ophthalmol* 1989; 33: 281 - 284.
6. Creig S Hoyt, William V Good: *Acute onset concomitant esotropia: when is it a sign of serious neurological disease?* *Br J Ophthalmol* 1995; 79: 498 - 501.

(contd. from page 46)

Assessment of retinal architecture requires knowledge of the OCT features of a normal eye. It is illustrated in figure 1. A highly reflective red layer present inferiorly, corresponds to the retinal pigment epithelium (RPE) and choriocapillaris. The contrast between this red layer and neural retina creates a reproducible boundary for measurement of neurosensory retinal thickness. The dark layer immediately anterior to the RPE / choriocapillaris represents the photoreceptor outer segment. The middle retinal layers exhibit moderate backscattering. Retinal blood vessels are noted by their shadowing of deeper retinal structures. The retinal nerve fibre layer corresponds to a bright red reflective layer at the inner retinal margin. The vitreoretinal interface is well defined due to contrast between the non-reflective vitreous and the backscattering retina. Weak reflections appear from the deep choroid and the sclera due to signal attenuation.

The data management system stores the information for future reference. OCT software package includes 18 scan acquisition protocols and 18 analysis protocols. Together they help us analyze the optic disc, the retinal nerve fiber layer and the macula with a single instrument. Thus OCT facilitates evaluation of both glaucoma and vitreoretinal diseases.

OCT is useful for detecting and monitoring a variety of diseases, including vitreomacular traction syndrome, macular hole, retinoschisis, macular edema, central serous chorioretinopathy, subretinal neovascularization, age-related maculopathy.<sup>3</sup>

The tomographic information provided by OCT has led to a better understanding of the pathogenesis of macular hole formation. OCT is effective in distinguishing full-thickness macular holes from partial-thickness holes, macular pseudoholes, and cysts.<sup>4</sup> OCT is useful in staging macular holes to identify potential surgical candidates. It can measure the diameter of macular hole, which can influence the post surgical outcome. In addition, hole resolution and macular thickness can be measured after surgery. OCT

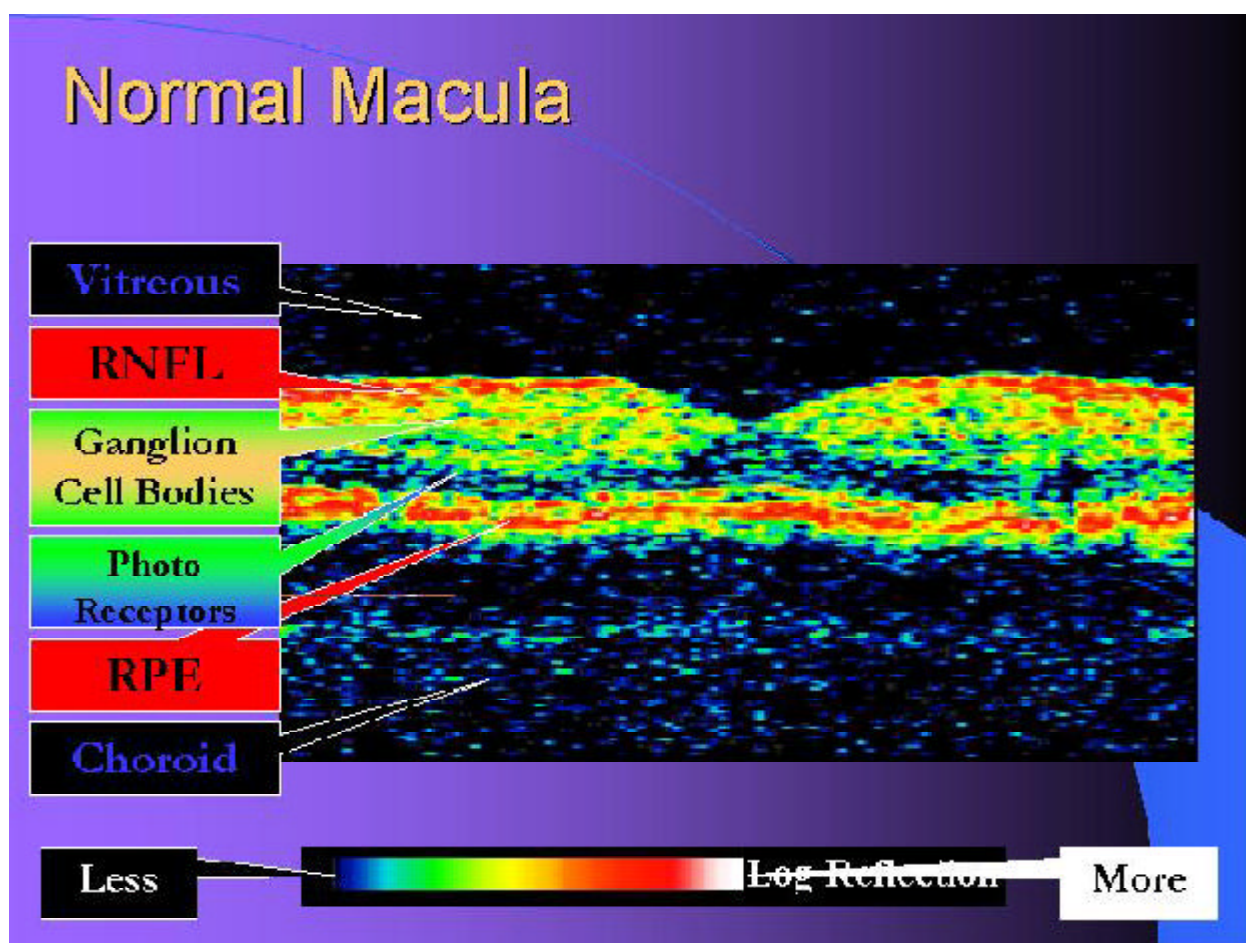


FIG.1- OCT picture of normal macula showing various layers of retina.

is also useful to evaluate the vitreofoveal interface in patients' fellow eye and is able to detect small (150 microns) separations of the posterior hyaloid from the retina.

OCT is useful for the diagnosis and quantitative characterization of epiretinal membranes.<sup>5</sup> The structural assessment of the macula is useful in the preoperative and postoperative evaluation of epiretinal membrane surgery. OCT can differentiate between the focally adherent membranes from globally adherent membranes. Globally adherent membranes are associated with features like macular pseudohole, a difference in optical reflectivity between the membrane and retina, and/or a visible membrane tuft or edge. Quantitative measurements and the assessment of membrane adherence with OCT may be useful in characterizing the surgical prognosis of eyes with an epiretinal

membrane.

OCT is a useful tool for evaluating, documenting and monitoring macular edema<sup>6</sup> with a very high degree of accuracy. It is sensitive to the small changes in retinal thickness. Macular edema is detected on OCT as intraretinal; areas of decreased reflectivity and retinal thickening. The various patterns detected are - diffuse spongy type of edema, cystoid macular edema and neurosensory retinal detachment. OCT is capable of detecting an early positive response to photocoagulation for macular edema.<sup>6</sup>

OCT has been used to evaluate various findings associated with ARMD<sup>7</sup>. It is helpful in quantitatively evaluating subretinal and intraretinal fluid, assessing possible subfoveal involvement of neovascularization, and in monitoring CNV before and after laser photocoagulation. Choroidal neovasculari



# Optical Coherence Tomography in Macular Disorders

Mahesh Shanmugam, Sachin Kabra and Pratik Ranjan Sen

The fundus view provided by traditional ophthalmoscopy is excellent. Techniques like fluorescein angiography, ultrasound and scanning laser ophthalmoscopy provides us with additional details such as functional and anatomical integrity of the retina and other structures of the fundus. However current diagnostic instruments lack sufficient resolution to provide useful cross-sectional images of retinal structure. High frequency ultrasound has resolution to about 20 microns but cannot be applied to posterior segment due to limited penetration. Ocular aberrations and the maximum entrance pupil diameter of the eye limit the longitudinal resolution of confocal imaging techniques such as scanning laser ophthalmoscopy to 300 microns. Optical coherence tomography (O.C.T.) is a novel noninvasive, noncontact-imaging modality, which produces high depth resolution (10 microns) cross-sectional tomographs of retina.<sup>1-3</sup>

OCT is a computer assisted precision optical instrument that works by a technique known as low-coherence interferometry. The principle of operation of interferometry is similar to ultrasound, except that it uses light rather than sound. The principle difference is that the speed of light is nearly a million times faster than the speed of sound. The difference permits measurement of structures and distances on the <10-micron scale, versus the 100-micron scale for ultrasound.

A near-infrared light beam (820 nm) is projected onto the retina from a super luminescent diode. An infrared camera is used to view the fundus and probe beam location. The light beam is reflected at the boundaries of tissues with different optical properties. The echo time delays of light reflected from the retina and reference mirror are compared. The interferometer combines the reflected light pulses from the retina and the reference mirror to create the interference, which is measured by a photodetector. The interfer-ometer electronically detects, collects, processes and stores the echo delay patterns from the retina. Multiple data points are integrated to construct a cross sectional image of retinal anatomy. The resultant OCT image of optical reflectivity is displayed in false color scale. It represents the degree of back-scattering from tissues at different depths in the retina. Dark colors such as blue and black represent regions of minimal relative optical reflectivity, while bright colors such as red and white represent regions of high optical reflectivity. The coherence length of the light source defines the longitudinal resolution of the OCT, which is about 10 microns. The transverse resolution is determined by multiple factors, including the probe beam diameter and the separation of individual A scans, and is upto 13 microns.

(contd. on page 43)

*This issue of Insight is sponsored by:*

**Rampion Eyetech Pvt. Ltd.**, Kalash, New Sharda Mandir Road, Paldi, Ahmedabad - 380 007

**Apex Laboratories Pvt. Ltd.**, 44, Gandhi Mandapam Road, Kotturpuram, Chennai - 600 085

**Pharmacia & Upjohn India Pvt. Ltd.**, SCO 27, Sector 14, Gurgaon 122 001, Haryana

**Warren Pharmaceuticals Ltd.**, 2/10, Joti Wire House, Veera Desai Road, Andheri (W), Mumbai - 400 053

**Medical & Vision Research Foundations thank the above sponsors for their generosity.**