

# insight

Vol. XXVII No. 3

OCTOBER 2009

Scientific Journal of  
**MEDICAL & VISION RESEARCH FOUNDATIONS**  
18, COLLEGE ROAD, CHENNAI - 600 006, INDIA

## Editorial

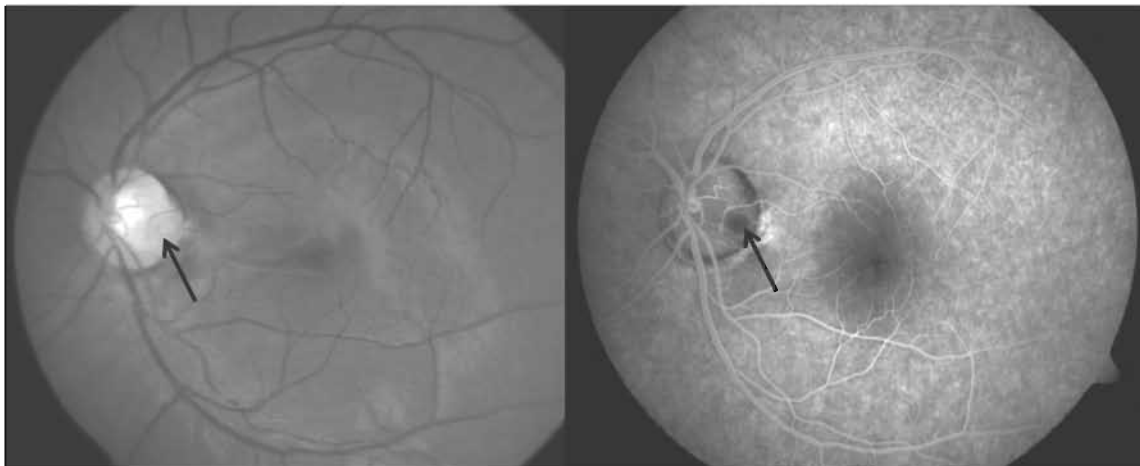
**Perspective — Optic disc pit and maculopathy — *Tandava Krishnan, Parveen Sen - Sri Bhagawan Mahavir Department of Vitreoretinal Sciences***

**Renal artery stenosis: associated risk factor in patients undergoing eye surgeries — *Ian Sundararaj, Bhanulakshmi Inder Mohan - Department of Anaesthesia***

**Paediatric puzzle — *Sanjeev Kumar, Sumita Agarkar - Department of Pediatric Ophthalmology***

**Introduction to Biostatistics-3 — Testing of assumptions — *M. Thennarasu, Dr. Vishnu Vahan Prasan, Dr. R. R. Sudhir - Department of Preventive Ophthalmology (Biostatistics & Epidemiology), Dr. V. V. Jaichandran - Department of Anesthesiology***

**Toxic anterior segment syndrome (TASS) — *Mohammad Arif - C.U. Shah Post Graduate Ophthalmic Institute***



## Editorial

Dear readers

This issue is special in that it covers a few areas hitherto not covered in our issues such as the optic disc pit and maculopathy and TASS. As always there is an intriguing muscle puzzle to keep the readers engrossed.

September 2009  
**S. Meenakshi**  
*Editor*

### AN APPEAL

A lot of things in this world depend on money - security, shelter, education and even health. But at Nethralaya, money has ceased to be a pre-requisite for sight.

Day after day, year after year, Nethralaya treats hundreds of patients absolutely free of cost and gives them back their sight.

Yet there is no discrimination between the free patient and the one who pays. Apart from the treatment, food, medicines and travel expenses are absolutely free.

Those free patients depend on Nethralaya, and Nethralaya depends on you.

So, come and join the **SANKARA NETHRALAYA OM TRUST INC.**

For questions about tax exempt status and contributions, please contact:

**Mr S V Acharya, Treasurer**

Sankara Nethralaya OM Trust Inc.

9710, Traville, Gateway Drive, Rockville, MD 20850, U.S.A.

Phone: (301)251 0378

INTERNET e-mail : [acharya@omtrust.org](mailto:acharya@omtrust.org), [snomtrustusa@yahoo.com](mailto:snomtrustusa@yahoo.com)

[www.omtrust.org](http://www.omtrust.org)

For those of you in India and elsewhere, please contact:

**Dr S S Badrinath, President & Chairman-Emeritus**

Sankara Nethralaya

(UNIT OF MEDICAL RESEARCH FOUNDATION)

18 College Road, Chennai 600 006

Phone: 2826 1265, 2827 1616 Fax: (044) 2825 4180, 2821 0117

INTERNET e-mail : [chairman@snmail.org](mailto:chairman@snmail.org)

LOOK US UP ON THE WEB at <http://www.sankaranethralaya.org>, <http://www.omtrust.org>

GIVE ONLINE @ [www.icicommunities.org](http://www.icicommunities.org)

Please notify change in your email to : [akila@snmail.org](mailto:akila@snmail.org) (or) [alagiri@snmail.org](mailto:alagiri@snmail.org)

**COME, GIVE THE GIFT OF SIGHT**

## Perspective

# Optic disc pit and maculopathy

Tandava Krishnan and Parveen Sen

Sri Bhagawan Mahavir Department of Vitreoretinal Sciences

Optic pits were first described by Wiethe in 1882.<sup>1</sup> They occur in less than 1 in 10,000 patients seen in an ophthalmic setting and are bilateral in 10–15% of cases.<sup>1</sup> Association of maculopathy with the optic disc pit was noted first by Reis in 1908.<sup>2</sup> Petersen<sup>3</sup> emphasized the relationship between congenital optic pits and a central serous chorioretinopathy-like picture for the first time in 1958. Kranenburg<sup>4</sup> in 1960 reported that two-thirds of 24 cases having the optic pit also had maculopathy, resulting in reduced visual acuity and central visual field defects.

Approximately one-third to two-thirds of patients with optic pits develop serous macular detachments.<sup>1</sup> This occurs mostly in the third and fourth decades and is usually associated with a poor visual prognosis. Numerous hypotheses with regard to the origin of the subretinal fluid, namely the cerebrospinal fluid, liquefied vitreous, permeable choroidal vessels or a permeable vessel in the pit, have been proposed. Other macular lesions associated with optic nerve pits include macular oedema, macular hole, macular cyst, schisis and pigment mottling. Gass proposed that serous detachment of the macula extending from the optic pit is the basic pathology that simulates these lesions and confirmed the same histopathologically by detecting fluid in subretinal space continuous with the optic pit.<sup>5–7</sup> Intrascitic haemorrhage was noted in a case of optic disc maculopathy with telangiectasia by Shauna *et al.*<sup>6</sup>

Optical coherence tomography (OCT) studies have given a further insight into the pathogenesis of maculopathy associated with optic disc pits. Krivoy *et al.*<sup>8</sup> used OCT to show schisis and/or macular detachment in three eyes with optic disc pits and suggested that the optic pit communicated with the schisis cavity in each of these eyes. This was subsequently confirmed by Meirelles *et al.*<sup>9</sup> These studies suggested the presence of a diaphanous membrane overlying the optic disc pit. Disruption of this membrane gives the liquefied vitreous access to the intraretinal layers through the communication existing between the optic disc pit and the retina.<sup>10</sup> A direct communication between the vitreous, the optic pit and the subretinal space was identified by Brown *et al.*<sup>11</sup> after injection of India ink into the vitreous of collies. This was subsequently proven in humans by other groups,<sup>1,12</sup> who noted the passage of intravitreal gas through the optic pit and into the subretinal space. These

findings supported the rhegmatogenous theory of the pathogenesis of subretinal fluid associated with optic disc pits. Additional indirect support for this hypothesis came from a study by Gopal *et al.*,<sup>13</sup> who found that retinal detachments that occurred in eyes with choroidal colobomas were associated with breaks in the diaphanous retinal tissue overlying the coloboma. The traction from the attached vitreous in the peripapillary area creates the necessary pull to create a break in the membrane overlying the pit. Moreover, it was observed that the spontaneous or surgical detachment of the vitreous resulted in resolution of the subretinal fluid.<sup>7,12,14</sup>

Theodossiadis *et al.*<sup>15</sup> suggested a grading system to identify the various stages of maculopathy (Table 1).

Grade	Finding
Grade 1	Schisis-like separation of inner layers of retina
Grade 2	Appearance of cystic changes in the macula
Grade 3	Lamellar macular hole/outer retinal layer detachment

Although optic nerve head pits are stationary, their associated retinal abnormalities may be progressive.<sup>9</sup> This progression was described in an OCT imaging study conducted in three patients having varying stages of maculopathy associated with the optic disc pit by Oswaldo *et al.*<sup>16</sup> The macular holes seen with optic disc pits differ from idiopathic macular holes in that the former often appear to have an intact, overlying internal limiting membrane.<sup>17</sup>

## NATURAL HISTORY AND MANAGEMENT PATTERNS

Optic disc maculopathy is associated with a poor visual prognosis. A study conducted at Wills Eye Hospital found that untreated eyes with optic disc pits and macular detachment had a vision less than 20/100 in 55% of the cases at a follow-up period of 1 year.<sup>17</sup> Treatment is directed towards the maculopathy associated with the optic disc pit. No treatment is usually initiated if an optic disc pit is seen without maculopathy. Management is in form of laser photocoagulation or surgery.

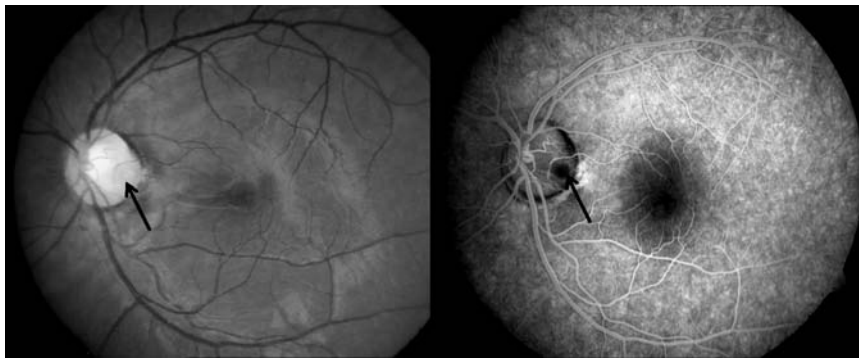

Figure 1. Colour fundus picture and fundus fluorescein angiography picture showing the optic disc pit (arrow).

### LASER PHOTOCOAGULATION

Brockhurst<sup>18</sup> was the first to report the effectiveness of laser therapy in the management of maculopathy associated with the optic disc pit. Chorioretinal adhesion is created by application of 2–3 rows of 200-micron light laser burns in peripapillary area adjacent to the optic disc pit. A red diode laser when used can minimize the damage to the underlying papillomacular bundle. Some patients complain of a scotoma following laser photocoagulation. However, this scotoma may be attributed to longstanding maculopathy and not a complication of laser therapy. Nevertheless, care needs to be taken to minimize the collateral damage.<sup>2</sup> The subretinal fluid usually resolves typically within weeks but in case of inadequate response, the procedure can be repeated after an interval of 2 months.<sup>2</sup> Laser-related reattachment was noted in five out of six cases in this series.<sup>18</sup> Laser photocoagulation has been suggested as the initial procedure in the management of these patients.<sup>19</sup> However, 44% of patients treated with laser had a vision

less than 20/100.<sup>2</sup> Also, photocoagulation response may be inadequate due to the presence of subretinal fluid in the peripapillary area. Hence, surgical intervention is needed in these cases.

### SURGICAL TREATMENT

Complete vitrectomy with induction of posterior vitreous detachment combined with drainage of the subretinal fluid endolaser to the margins of the optic disc pit followed by gas tamponade is the usual procedure followed. The combination of laser and vitrectomy with gas tamponade results in the removal of the source of fluid as well as obliterates the communication between the optic disc pit and the cavity. A 360-degree peripapillary endophotocoagulation treatment after pars plana vitrectomy for the treatment of optic nerve pit-associated retinal detachment was attempted in a series of two cases and resulted in good visual recovery and retinal reattachment at a follow-up of 6 months.<sup>20</sup> Pars plana vitrectomy with internal gas tamponade

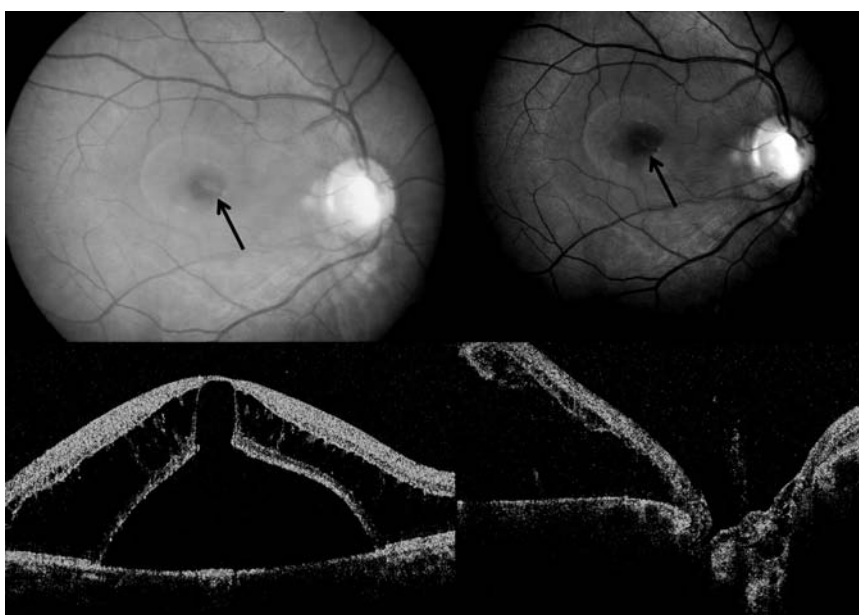


Figure 2. Colour fundus picture and red-free photograph depicting optic disc maculopathy (arrow). The corresponding OCT pictures of the patient show retinoschisis with subretinal fluid accumulation in the macular area with optic disc pit.

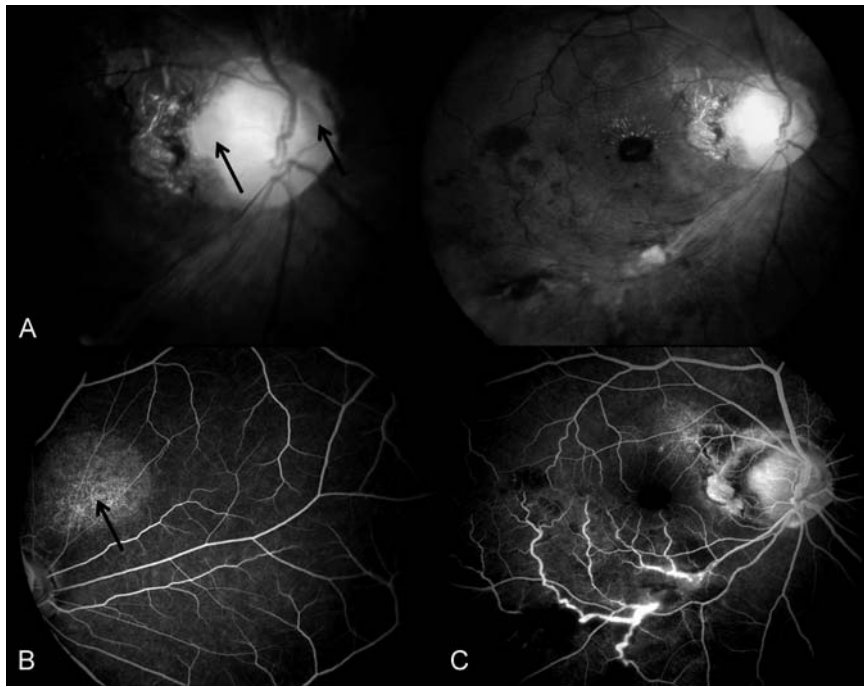


Figure 3. (A) A rare case of optic disc pit seen on temporal and nasal aspects of the optic disc (arrow) associated with vasculitis and premacular haemorrhage. (B) RPE alterations noted nasal to the nasal optic disc (arrow) suggestive of absorbed SRF. (C) FFA features of BRVO secondary to vasculitis.

was also found to be promising in the case of optic disc with retinoschisis with macular hole after unsuccessful laser therapy.<sup>20,21</sup> Lincoff and Kreissig<sup>23</sup> performed pneumatic displacement of central retinal elevation to below the inferior vascular arcade in three cases with a resulting improvement in visual acuity, although the effect of the procedure was temporary. Internal drainage after vitrectomy by creating a communication between outer schisis-like separation and the vitreous cavity and thus to interrupt the continuous flow into the subretinal space was attempted in a case. The incision was made parallel to the papillomacular bundle, approximately 3/4 deep into the retina using a bent 27-gauge cannula without any active suction of the subretinal fluid. The vision improved from 20/400 to 20/20 over a period of 1 year and remained stable over a follow-up period of 29 months.<sup>24</sup> Spaide *et al.*<sup>25</sup> also attempted a similar procedure with a resultant decrease in macular thickness and improvement in visual acuity, which was seen for a follow-up period of 12 months. Macular buckling surgery for treatment of maculopathy was attempted in a group of 10 patients.<sup>26</sup> Multifocal electroretinogram was used as a means to assess the retinal sensitivity before and after the procedure. It was found that there was a reduction in sensitivity in the foveal and parafoveal area which gradually improved after the procedure in all the cases over a period of 18 months. Visual acuity also improved in the same series in 8 out of the 10 cases.<sup>26</sup> Use of multiple procedures by various vitreoretinal surgeons probably points towards the non-satisfactory end—point or visual outcome associated with these cases in spite of active surgical intervention. Laser therapy for symptomatic patients continues to be the primary modality of treatment.

## REFERENCES

1. Postel EA, Pulido JS, McNamara JA, Johnson MW. The etiology and treatment of macular detachment associated with optic nerve pits and related anomalies. In *The American Ophthalmological Society 134<sup>th</sup> Annual Meeting*, Hot Springs, VA, May 1998.
2. Yanoff M, Duker JS. *Ophthalmology*, 3rd ed., Mosby Publications, 2008.
3. Petersen HP. Pits or crater-like holes in the optic disc. *Arch. Ophthalmol.* 1958; 36: 435–43.
4. Kranenburg EW. Crater-like holes in the optic disc and central serous retinopathy. *Arch. Ophthalmol.* 1960; 64: 912–24.
5. Gass JDM. Serous detachment of the macula. *Am. J. Ophthalmol.* 1969; 67: 821–41.
6. Quinn SM, Charles SJ. Telangiectasis as a cause of intra-schitic haemorrhage in optic disc pit maculopathy. *Acta Ophthalmol. Scand.* 2004; 82: 93–5.
7. Hirakata A, Hida T, Ogasawara A, Iizuka N. Multilayered retinoschisis associated with optic disc pit. *Jpn. J. Ophthalmol.* 2005; 49: 414–6.
8. Krivoy D, Gentile R, Liebmann JM *et al.* Imaging congenital optic disc pits and associated maculopathy using optical coherence tomography. *Arch. Ophthalmol.* 1996; 114: 165–70.
9. Meirelles RL, Aggio FB, Costa RA, Farah ME. STRATUS optical coherence tomography in unilateral colobomatous excavation of the optic disc and secondary retinoschisis. *Graefes Arch. Clin. Exp. Ophthalmol.* 2005; 243: 76–81.
10. Sugar HS. Congenital pits in the optic disc with acquired macular pathology. *Am. J. Ophthalmol.* 1962; 53: 307–11.
11. Brown GC, Shields JA, Patty BE *et al.* Congenital pits of the optic nerve head: experimental studies in collie dogs. *Arch. Ophthalmol.* 1979; 97: 1341–4.
12. Bonnet M. Serous macular detachment associated with optic nerve pits. *Graefes Arch. Clin. Exp. Ophthalmol.* 1991; 229: 526–32.
13. Gopal L, Badrinath SS, Sharma T *et al.* Pattern of retinal breaks and retinal detachments in eyes with choroidal colobomas. *Ophthalmology* 1995; 102: 1212–7.
14. Besada E, Barr R, Schatz S, Brewer C. Vitreal pathogenic role in optic pit foveolar retinoschisis and central serous chorioretinopathy. *Clin. Exp. Optom.* 2003; 86(6): 390–8.

15. Theodossiadis GP, Theodossiadis PG, Ladas ID, Zafirakis PK, Kollia ACK, Koutsandrea C, Vergados I, Apostolopoulos MN. Cyst formation in optic disc pit maculopathy. Documenta Ophthalmologica. Adv. Ophthalmol. 1999; 97(3-4): 329-35.
16. Oswaldo Ferreira Moura Brasil, Maria Vitoria Oliveira Moura Brasil, Oswaldo Moura Brasil. Different presentations of intraretinal fluid collections in optic disc pits: OCT study of 3 cases. Arq. Bras. Oftalmol. 2006; 69(5): 745-7.
17. Brown GC, Shields JA, Goldberg RE. Congenital pits of the optic nerve head. II. Clinical studies in humans. Ophthalmology 1980; 87: 51-65.
18. Brockhurst RJ. Optic pits and posterior retinal detachment. Trans. Am. Ophthalmol. Soc. 1975; 73: 264-91.
19. Falcone PM, Lou PL. Resolution of an external layer macular hole associated with an optic nerve pit after laser photocoagulation. Br. J. Ophthalmol. 1993; 77: 457-9.
20. Bakri SJ, Beer PM. Vitreoretinal surgery for optic pit associated serous macular detachment: a discussion of two cases. Int. Ophthalmol. 2004; 25: 143-6.
21. Gupta A, Srinivasan R, Kaliaperumal S, Sengupta S. Pars plana vitrectomy for macular detachment with optic disc pit. Asian J. Ophthalmol. 2006; 8: 153-5.
22. Snead MP, James N, Jacobs PM. Vitrectomy, argon laser and gas tamponade for serous retinal detachment associated with an optic disc pit: a case report. Br. J. Ophthalmol. 1991; 75: 381-2.
23. Lincoff H, Kreissig I. Optical coherence tomography of pneumatic displacement of optic disc pit maculopathy. Br. J. Ophthalmol. 1998; 82: 367-72.
24. Schaal KB, Wrede J, Dithmar S. Internal drainage in optic pit maculopathy. Br. J. Ophthalmol. 2007; 91: 1093.
25. Spaide RF, Fisher Y, Ober M, Stoller G. Surgical hypothesis: inner retinal fenestration as a treatment for optic disc pit maculopathy. Retina 2006; 26(1): 89-91.
26. Theodossiadis G, Theodossiadis P, Malias J, Moschos M, Moschos M. Preoperative and postoperative assessment by multifocal electroretinography in the management of optic disc pits with serous macular detachment. Ophthalmology 2002; 109: 2295-302.



## **Elite School of Optometry- Sankara Nethralaya**

(Unit of Medical Research Foundation)

### **Pediatric Optometry Fellowship**

Pediatric Optometric Fellowship – Six months Programme

**Prerequisites:**

- **B S degree in optometry or its equivalent degree in optometry**  
**(or)**
- **Diploma in Optometry/ Refraction with minimum 2 years of clinical experience**
- **Competitive Mark in the course previously done**

For details about the courses, please visit [www.sankaranethralaya.org/op\\_Elite.htm](http://www.sankaranethralaya.org/op_Elite.htm)  
or

Write to The Program Coordinator, Pediatric Optometry Fellowship,  
Elite School of Optometry, No.8, G S T Road, St. Thomas Mount, Chennai 600016  
Email : [elite@snmail.org](mailto:elite@snmail.org), Phone: 91-44-22349269/ 22346023

PLEASE LOOK US UP ON THE WEB at  
<http://www.sankaranethralaya.org>

Please forward your correct address with your E-mail address if any,  
to [insight@snmail.org](mailto:insight@snmail.org) to enable us to update our address data base.

**INSIGHT & EYELIGHTS are now available on line at**  
<http://www.sankaranethralaya.org/publication.htm>

# Renal artery stenosis: associated risk factor in patients undergoing eye surgeries

Ian Sundararaj and Bhanulakshmi Inder Mohan

Department of Anaesthesia

## INTRODUCTION

Renal artery stenosis (RAS) is the narrowing of the renal artery, most often caused by atherosclerosis or fibromuscular dysplasia. This narrowing of the renal artery can impede blood flow to the kidney. Most cases of RAS are asymptomatic, and the main problem is high blood pressure that cannot be controlled with standard medication which is also known as renovascular hypertension (RVHT). Deterioration in renal function may develop if both kidneys are poorly supplied or when treatment with an ACE inhibitor is initiated. Some patients present with episodes of flash pulmonary oedema (sudden left ventricular heart failure).

RAS causing secondary hypertension is becoming increasingly common because of atherosclerosis in an aging population. Patients with cataract and vitreoretinal disease usually present with hypertension and varying degrees of renal impairment. RAS may be present in some patients even with normal or low blood pressure due to the administration of drugs with cardiac and anti-hypertensive action for the treatment of angina or heart failure which may reduce the blood pressure. Normal or lower than normal blood pressure may also be due to severely depressed cardiac output. Atheromatous RAS although thought to be a cause of hypertension is not commonly associated with mild-to-moderate hypertension. However, it is present up to a third of patients with malignant or drug-resistant hypertension.

## CASE REPORT

A 68-year-old male patient with a history of hypertension and diabetes on medication was operated on 3 November 2006 for right eye cataract surgery.

At the time of admission, his blood pressure was 130/90 mmHg and blood sugar was 111 mg%. On transferring him into the operation theatre from the ambulatory ward, his BP increased to 230/88 mmHg. He was given sublingual 5 mg nifedipine. After 10 min, his blood pressure recorded was 124/56 mmHg.

After the local anaesthesia block and during surgery, his BP was recorded every 10 min and ranged between 146/72 and 129/69 mmHg. His heart rate ranged between 100 and 88 per min. Postoperative blood pressure was 130/70 mmHg and postoperative period was uneventful.

After more than 1 year, the same patient presented for cataract surgery of the other eye. This time, he had a

history of left ventricular failure and cardiac arrest (2007) from which he was resuscitated. All the reports and investigations done at that time were reviewed. (Physical fitness for surgery was sought from the patient's cardiologist.)

The patient's renal and cardiac work-up were as follows and a diagnosis of RAS was made:

- Coronary arteriography: distal left main artery showed mild 30% lesion. LAD, diagonal and septal perforators were normal. LCX and OM branches, RCA, RCA branches PDA and PLB were all normal. Right renal artery had a 90% lesion. Left renal artery was normal. Impression was right renal artery stenosis. Abdominal aortogram showed calcified aorta with 80% stenosis near the right renal artery. Right renal artery had 90% stenosis at the origin.
- Ultrasound abdomen: right kidney measured  $9.8 \times 3.8$  cm and left kidney measured  $9.8 \times 4.9$  cm.
- TC-99m EC with Lasix diuretic renal study showed mild reduction in perfusion of both kidneys. Both the kidneys showed mild reduction in tracer concentration. The intra-renal transit was normal on both sides. There was excretion into both pelvis, ureters and into the bladder. No evidence of obstruction to drainage was seen. Post-void pictures showed normal emptying of bladder.
- Total glomerular filtration rate (GFR) is approximately equal to 63 ml/min (normal lower limit of GFR for age is 73 ml/min).
- Relative renal function: left kidney = 54% (34 ml/min). Right kidney = 46% (29 ml/min). This indicated a mild reduction in perfusion and function of both kidneys with no obstruction to drainage.
- Echocardiogram: showed LVH due to SHT. Aortic valve calcification mild. Aortic regurgitation mild. Left ventricular functions—LVEDV, 166 cm<sup>3</sup>, LVSV, 51 cm<sup>3</sup>; EF, 70%.

The patient was operated for left eye cataract on 26 March 2008. At the time of pre-anaesthetic evaluation, his systolic blood pressure was 157/80 mmHg and RBS was 64 mg%.

On admission, the blood pressure was 170/80 mmHg. On entry into OT, his BP was 192/72 mmHg. The patient was given midazolam 1 mg IV and then the local anaesthetic block was given. The intraoperative BP ranged between 133/57 mmHg (75) and 149/63 mmHg (82) and the heart rate ranged between 88 and

75 per min. Postoperatively, BP was 160/80 mmHg and postoperative period was uneventful.

## DISCUSSION

Renal vascular disease accounts for less than 1% of all hypertension in people who have moderately increased blood pressure. But in certain high-risk groups, renal vascular disease may be the cause of 10–40% of all hypertension.

## PATHOPHYSIOLOGY

RVHT is the clinical consequence of renin–angiotensin–aldosterone activation. Since Goldblatt's work in 1934, RVHT has become increasingly recognized as a cause of clinically difficult-to-control hypertension and chronic renal insufficiency. Goldblatt demonstrated that occlusion of the renal artery causes ischaemia, which then causes an elevation of blood pressure by triggering the release of renin. Increased renin levels help in the conversion of angiotensin I to angiotensin II, causing severe vasoconstriction and aldosterone release.

RAS is a major cause of RVHT and accounts for 1–10% of the 50 million cases of hypertension in the United States.

RAS is narrowing of the renal artery, most often caused by atherosclerosis or fibromuscular dysplasia. This narrowing of the renal artery can impede blood flow to the target kidney. Atherosclerosis is the predominant cause of RAS in the majority of patients, usually those with sudden hypertension at age of 50 or more. It typically occurs in male smokers with coexisting vascular disease. Fibromuscular dysplasia is the predominant cause in young patients, usually females under 40 years of age.

RAS causes high blood pressure and damages the kidneys. Damaged kidneys can make blood pressure even higher. If untreated, this vicious cycle can lead to kidney failure and damage the heart and blood vessels throughout the body.

The use of ACE inhibitors can cause deterioration of renal functions.

In a kidney rendered ischaemic by RAS with reduced afferent blood flow, the intraglomerular pressure and glomerular filtration (GF) are maintained by angiotensin II mediated efferent vasoconstriction. Removal of the efferent vasoconstriction effect by using angiotensin blockade in the ischaemic kidney may reduce the GFR. ACE inhibitors eliminate efferent vasoconstriction and cause a decrease in the intraglomerular pressure and the GFR and can cause deterioration of renal functions.

## RISK FACTORS FOR RAS

- Carotid artery disease
- Coronary artery disease
- Diabetes mellitus
- Hypertension
- Obesity
- Age
- Peripheral vascular disease
- Smoking.

## CLINICAL FEATURES

- Patients usually with no family history of hypertension
- Young hypertensive
- Peripheral vascular disease
- Resistant hypertension (high blood pressure not responding to two or more drugs)
- Deteriorating blood pressure control in longstanding hypertensive patients
- Renal impairment with minimal proteinuria
- History of acute left ventricular failure (flash pulmonary oedema)
- >1.5 cm difference in kidney size on ultrasonography and
- Auscultation reveals a bruit on the affected side, inferior of costal margin.

## DIAGNOSIS

- Ultrasound
- Angiogram: more accurate diagnosis of RAS
- CT scan and MRA.

## TREATMENT

- Antihypertensive medication
- Cholesterol-lowering drugs.

## FLASH PULMONARY OEDEMA

Acute recurrent pulmonary oedema in association with RAS was first described by Pickering *et al.* It differs from left ventricular failure with pulmonary oedema in that this condition is usually associated with severe left ventricular *systolic* dysfunction. It is mostly nocturnal and comes rather suddenly. Flash pulmonary oedema is probably a consequence of fluid retention and diastolic ventricular dysfunction which often accompanies (bilateral) atheromatous RAS. It usually responds to standard methods of treatment including diuretics. Occasionally, it may be more serious and require ventilation.

## CONCLUSION

Essential hypertension is prevalent in patients who present for eye surgery at the time of pre-anaesthetic evaluation. Secondary hypertension mostly gets unnoticed and patients get operated without being diagnosed. Special attention should be given to those patients with severe hypertension who do not respond to standard treatments. RVHT poses interesting challenges to the physician and anaesthetist and must be borne in mind when managing patients who do not respond to standard antihypertensive regimes.

## REFERENCES

1. Kramer K, Kirkman P, Kitzman D, Little WC. Flash pulmonary edema: association with hypertension and reoccurrence despite coronary revascularization. *Am. Heart J.* 2000; 140(3): 451–5.
2. Pickering TG, Herman L, Devereux RB, Sotelo JE, James GD, Sos TA, Silane ME, Laragh JH. Recurrent pulmonary oedema in hypertension due to bilateral renal artery stenosis: treatment by angioplasty or surgical revascularisation. *Lancet* 1988; 2(8610): 551–2.



# Paediatric puzzle

Sanjeev Kumar and Sumita Agarkar

*Department of Pediatric Ophthalmology*

A 5-year-old female child reported to clinic with her father with the complaint of deviation of right eye inwards since birth. Birth history was uneventful and her birth weight was normal. Her other developmental activities were within normal, and performance at school was good. The parents were healthy without any history of consanguinity. There was no family history of any congenital malformation or any neurological abnormality.

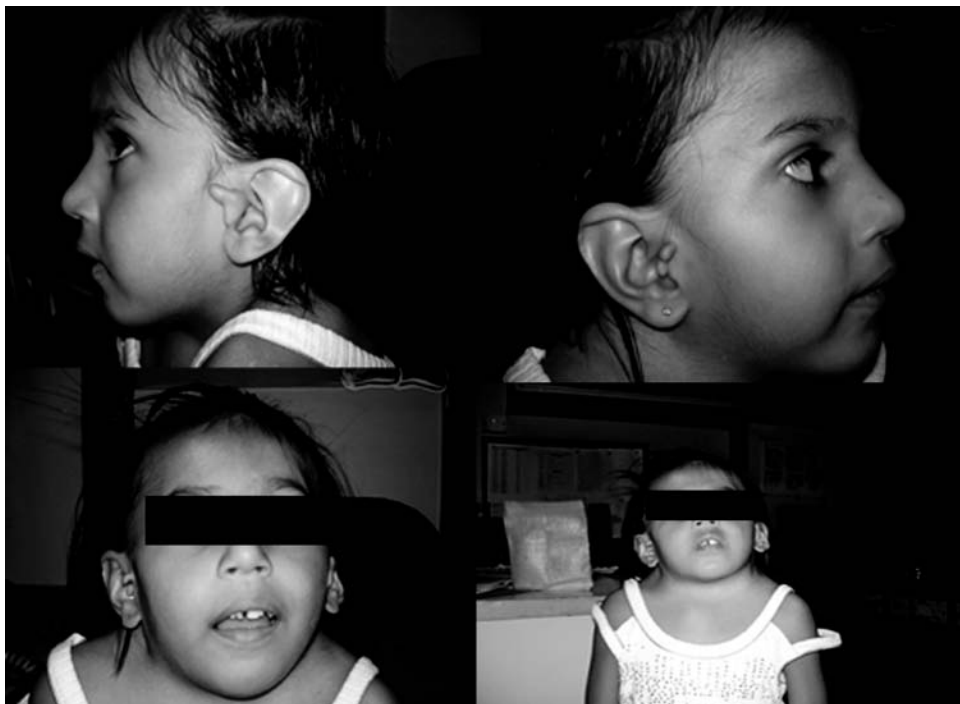On physical examination, she had facial asymmetry, flat occiput, bilateral preauricular tags and very short and webbed neck with head tilt to right.

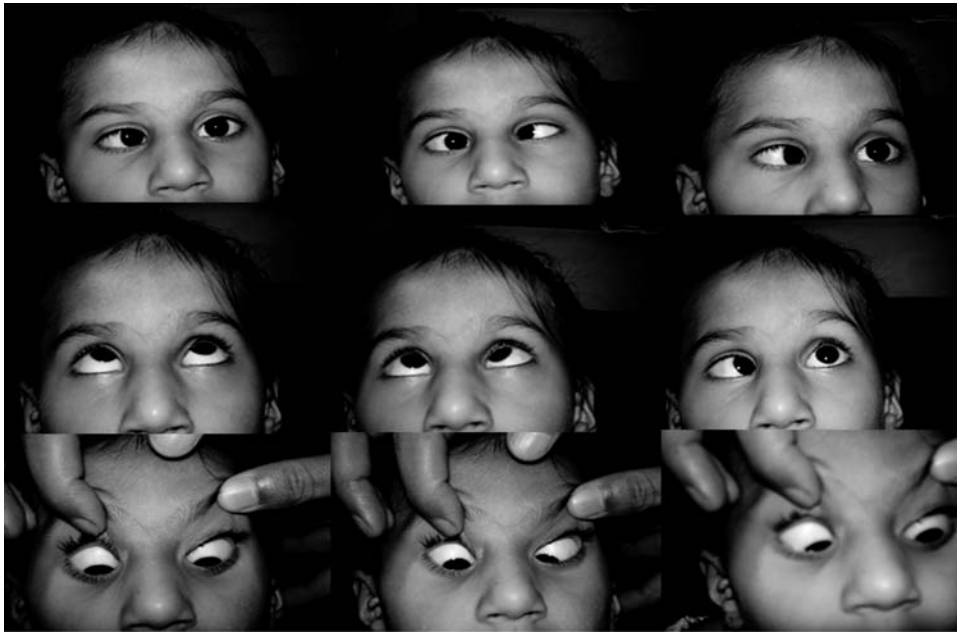Ocular examination showed unaided visual acuity of 6/18 in the right eye and 6/12 in the left eye with

Snellen's test types. The fixation pattern in the right eye showed central, steady unmaintained, whereas in the left eye showed central, steady and maintained. Hirschberg test showed right convergent squint. Cover test for distance and near showed right convergent squint to alternate convergent squint.

Sensory evaluation with Worth 4 Dot test and Randot test showed unreliable responses extraocular movement showed bilateral abduction limitation. Post dilated flash in the right eye: +4.50DS/-1.25DCX170; left eye: +4.00DS/-1.25 DCX180. On Slit lamp examination, anterior segment was within normal limits. Fundus examination by indirect ophthalmoscope was found to be within normal limits.

## WHAT IS YOUR DIAGNOSIS?





## WILDERVANCK SYNDROME

Wildervanck syndrome, also known as cervico-oculoacoustic syndrome, is a rare genetic disorder that primarily affects females. Initially described by Wildervanck<sup>1</sup> in 1952, this syndrome is characterized by deafness, Klippel-Feil anomaly and Duane's retraction syndrome. There may be facial asymmetry, short and webbed neck, low hairline and preauricular skin tags. Other spinal abnormalities such as torticollis, scoliosis or Sprengel deformity have also been described. The other features of Wildervanck syndrome that are found occasionally are: occipital meningocele, cerebellar and Brainstem hypoplasia, cervical diastematomyelia, pseudopapilledema,<sup>2</sup> subluxation of lens,<sup>3</sup> epibulbar dermoid,<sup>4</sup> paradoxical lacrimation, hydrocephalus, cleft palate, cardiac defect (ASD), cervical rib, absent kidney and cholelithiasis.

In this patient, there was facial asymmetry, short and webbed neck, preauricular skin tags, Klippel-Feil anomaly and bilateral abduction limitation. This patient had no deafness, no globe retraction, and palpebral fissure changes on adduction were absent. But still my diagnosis is Wildervanck syndrome. As Wildervanck<sup>5</sup> himself observed variable expressivity of this syndrome and suggested that only two characteristics of the triad are needed to make the diagnosis. This syndrome is responsible for at least 1% of deafness among girls.<sup>6</sup>

The exact aetiology of this disorder is unknown. The syndrome is genetically limited to females which suggest X-linked dominant transmission with lethality

in males. Others think that multifactorial inheritance is more likely.<sup>7</sup>

Radiological evaluation by X-ray may show cervical scoliosis with fusion of cervical vertebra. Computed tomography may demonstrate the abnormalities of middle ear structures and semicircular canals. Magnetic resonance imaging for craniospinal abnormalities should be considered.

The handicaps in this syndrome remain stationary throughout life and apparently do not influence life span. Intelligence in the vast majority of cases is normal.

## REFERENCES

1. Wildervanck LS. The cervico-oculoacoustic syndrome. In: Vinken PJ, Bruyn GW, Myrianthopoulos NC (eds). *Congenital Malformations of the Spine and Spinal Cord. Handbook of Clinical Neurology*, vol. 32. New York: North-Holland Publishing, 1978, pp. 123-30.
2. Kirkham TH. Cervico-oculoacoustic syndrome with pseudopapilloedema. *Arch. Dis. Child* 1969; 53: 335-9.
3. Strisciuglio P, Raia V, Di Meo A *et al.* Wildervanck's syndrome with bilateral subluxation of lens and facial paralysis. *J. Med. Genet.* 1983; 20: 72-3.
4. Kirkham TH. Duane's syndrome and familial perceptive deafness. *Br. J. Ophthalmol.* 1969; 53: 335-9.
5. Wildervanck LS. Een cervico-oculoacousticussyndroom. *Ned. Tijdschr. Geneesk.* 1960; 104: 2600-5.
6. McKusick VA. *Mendelian inheritance in man: catalogs of autosomal dominant, autosomal recessive and X-linked phenotypes*, 5th edn. Baltimore: Johns Hopkins University Press, 1978, pp. 806-7.
7. Konigsmark BW, Gorlin RJ. *Genetic and Metabolic Deafness*. Philadelphia, PA: Saunders, 1976, pp. 188-91.

## Introduction to biostatistics-3

# Testing of assumptions

M. Thennarasu<sup>1</sup>, Dr. V. V. Jaichandran<sup>2</sup>, Dr. Vishnu Vahan Prasan<sup>1</sup>  
and Dr. R. R. Sudhir<sup>1</sup>

<sup>1</sup>Department of Preventive Ophthalmology (Biostatistics & Epidemiology)

<sup>2</sup>Department of Anesthesiology

## INTRODUCTION

In the previous article, we saw the various tools that are available in a descriptive statistics. Now, in this article, we will discuss about the various methods available for testing assumptions. In statistical analysis, all statistical tools assume some assumptions. Violation of these assumptions changes the conclusion of the research. Therefore, all research, whether it is a journal article or thesis, must follow these assumptions.

The following are the statistical tools used for testing of assumptions: normality, homogeneity of variance, independence assumptions, randomness, equality of means and multicollinearity.

### Assumptions of normality

#### What is normal distribution?

Normal distribution is a continuous probability distribution that describes data that cluster around a mean or average. It is also called as Gaussian distribution. The graph of the normal distribution is bell-shaped, with a peak at the mean, and is known as the Gaussian function or bell-curve (see Figure 1).

Following are the properties of normal distribution:

1. The curve is symmetric about the mean.
2. The mean, median and mode are equal and are located at the centre of the distribution.
3. A normal distribution curve is unimodal, i.e. it has only one peak.
4. The curve never touches the  $x$ -axis.
5. The total area (probability) under a normal distribution is equal to 1.00 or 100%.
6. The normal distribution is characterized by two parameters: the mean  $\mu$  (mu) and standard deviation  $\sigma$  (sigma).
7. The mean is a measure of location or centre of the graph. The standard deviation is a measure of spread, determined by the height and width of the graph.
8. The mean can be any value between  $\pm$ infinity, and the standard deviation must be positive.
9. The mean and the standard deviation of the standard normal distribution is 0 and 1, respectively.

10. Every normal curve conforms to the following "rule":

- About 68% of the area under the curve falls within 1 standard deviation of the mean.
- About 95% of the area under the curve falls within 2 standard deviations of the mean.
- About 99.7% of the area under the curve falls within 3 standard deviations of the mean.

#### How useful is testing of normality?

Many data analysis methods ( $t$ -test, ANOVA, regression, etc.) depend on the assumption that data were sampled from a Gaussian distribution. Normality tests show that whether the data collected is deviated from the normal bell-shaped distribution or not. For practical purpose, 3 standard deviation ( $3\sigma$ ) means 99.14% of the data collected were normal,  $2\sigma$  means 95.44% of the data values were normal and  $1\sigma$  means 68.26% of the data were normal.

It is important that we check the normality of the quantitative outcome variable so as to allow us not only to present the appropriate descriptive statistics, but also to apply the correct statistical tool for testing of null hypothesis. Remember that for studies with smaller sample size ( $n < 10$ ), normality test do not have much power to detect non-Gaussian distributions.

#### Testing of normality—different methods

1. Graphical representation.
2. Descriptive statistics (skewness and kurtosis).
3. Formal statistical tests.

#### Graphical method for test of normality

The following graphical methods are used for testing of normality of data.

- a. Box plot
- b. Histogram
- c. P-P plot
- d. Q-Q plot.

**Box plot.** The box plot is a graphical display of a five-number (upper range value, lower range value, 25th, 50th and 75th percentile value) summary.<sup>1</sup> Sometimes the box plot is also known as a box and whiskers plot.

Here are the four steps to be followed for the construction of box plot (see Figure 2):

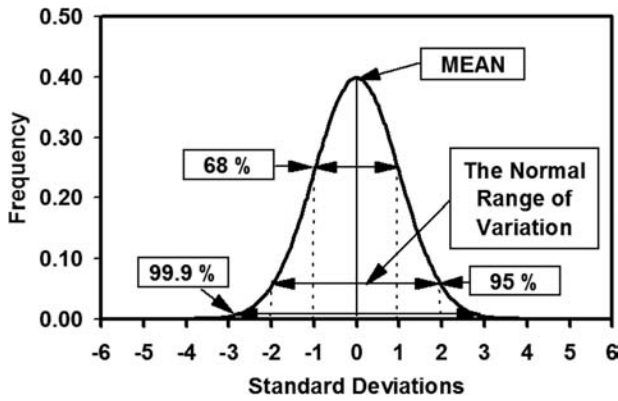


Figure 1. Normal distribution curve.

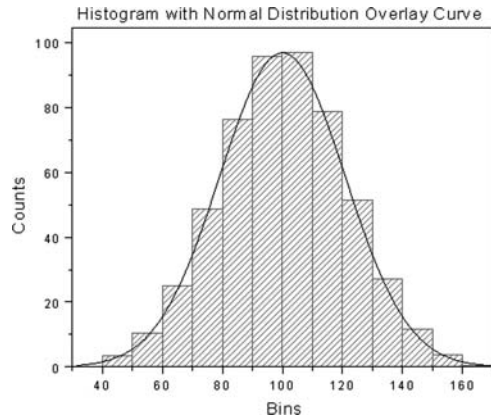


Figure 4. The classical bell-shaped, symmetric histogram with most of the frequency counts bunched in the middle and with the counts dying off in the tails.

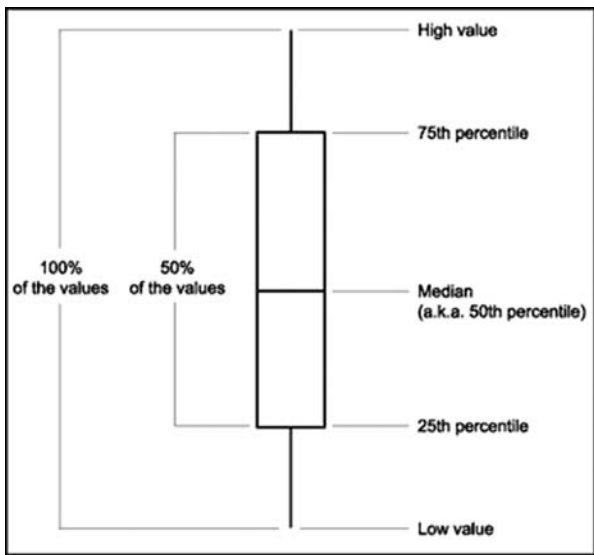


Figure 2. Box plot showing five-number summary statistics.

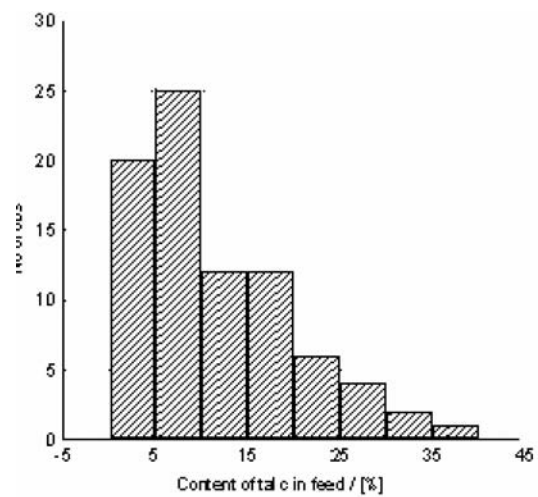


Figure 5. A histogram showing an abnormal distribution.

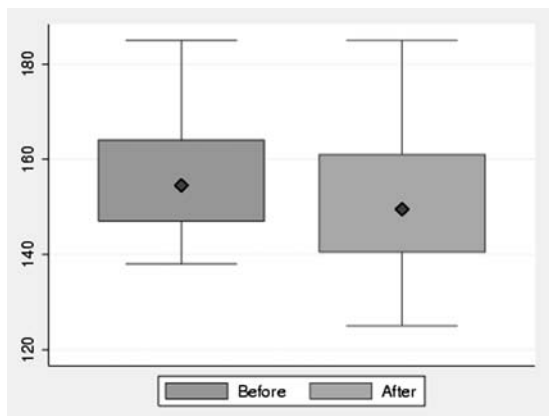


Figure 3. A sample box plot.

1. Draw a box from the 25th to the 75th percentile.
2. Split the box with a line at the median.
3. Draw a thin line (whisker) from the 75th percentile up to the maximum value.
4. Draw another thin line from the 25th percentile down to the minimum value.

*Applications:* Box plots are helpful in quality analysis for interpreting the distribution of data because they can

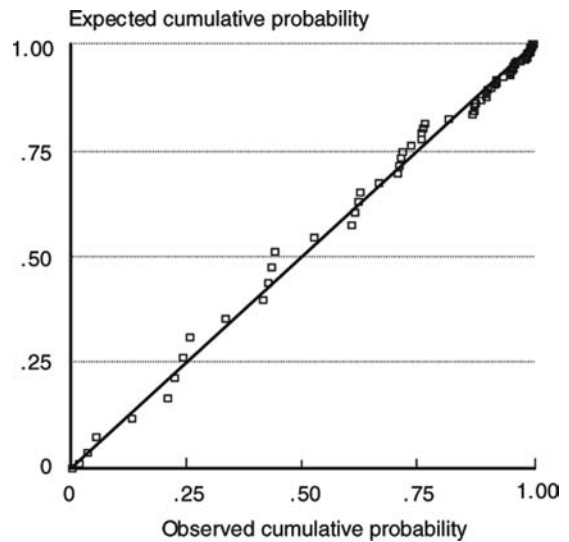


Figure 6. A P-P plot showing a normal distribution pattern.

easily show whether the data is skewed (abnormal) and any unusual observations (outliers) in the data set. Box plots are also very useful when large number of observations are involved and when two or more data sets are being compared.

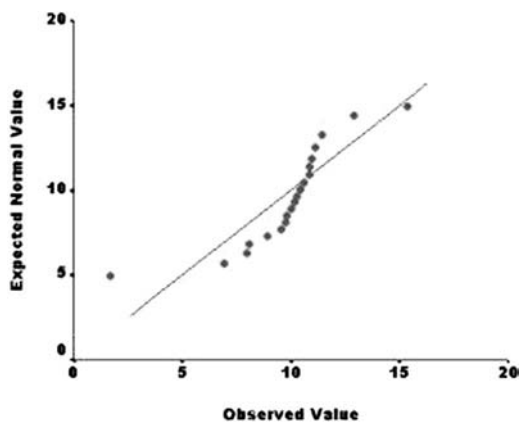


Figure 7. A P-P plot with abnormal distribution, points not clustered around the straight line.

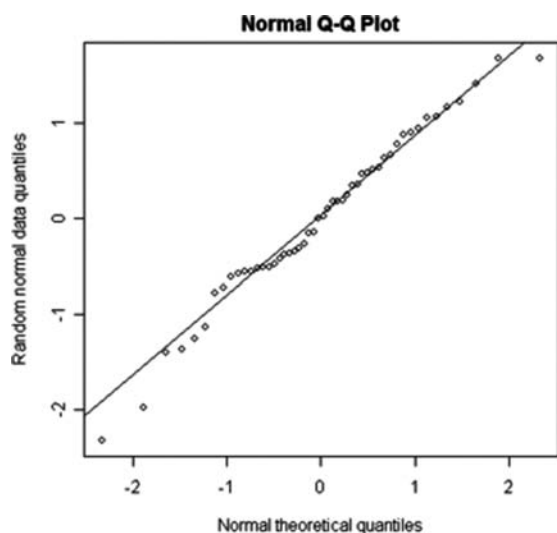


Figure 8. A Q-Q plot with a normal distribution.

**Histogram.** In statistics, a histogram is a graphical display of tabulated frequencies, shown as bars, in which the vertical axis represents the count (frequency) and the horizontal axis represents the possible range of the data values. It shows what proportion of cases fall into each of several categories.

**Applications:** A histogram is a useful device for exploring the shape of the distribution of the values of a variable. Histograms are used for screening of outliers, checking normality or suggesting another parametric shape for the distribution.

**P-P plot.** The P-P plot (probability plot) is a graphical technique for assessing whether or not a data set follows a given distribution such as the normal. In the P-P plot, observed cumulative probabilities of occurrence is plotted on the x-axis and expected cumulative probabilities of occurrence on the y-axis. If the selected variable matches the normality, then the points will cluster around a straight line and if the points vary more from a straight line, then selected variable is not normally distributed.

**Q-Q plot.** The Q-Q or quantile-by-quantile plot plots the quantiles of a variable's distribution against the quantiles

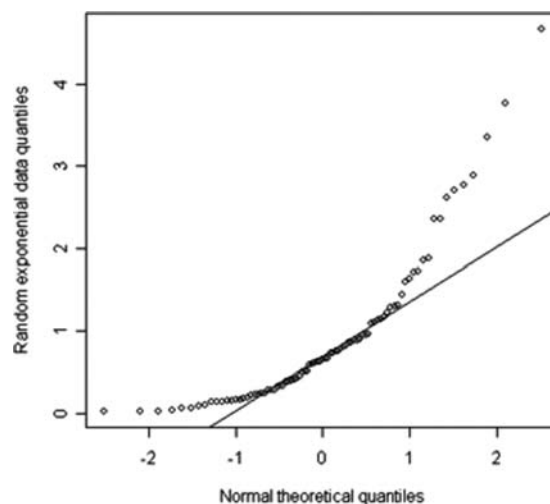


Figure 9. A Q-Q plot showing the abnormal distribution.

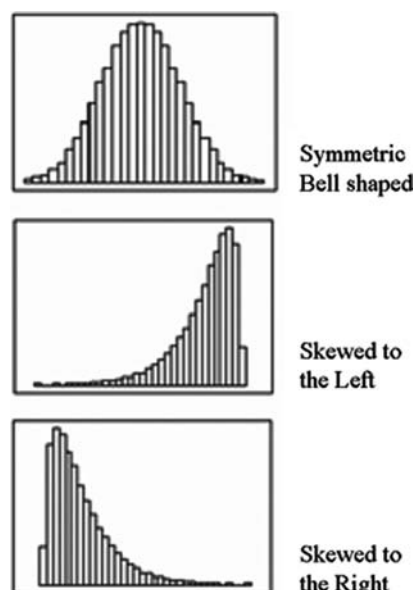


Figure 10. A symmetric and a asymmetric distributions.

of the test distributions. It is generally used to determine whether the distribution of a variable matches a given distribution.

## Descriptive statistics (skewness and kurtosis)

### Skewness

The term “skewed” is used to refer something that is out of line or distorted on one side. When referring to the shape of the frequency or the probability distributions, skewness refers to the measure of the degree of asymmetry of a distribution. Skewness that is normal involves a perfectly symmetric distribution. A distribution with asymmetric tail extending out to the right is referred to “positively skewed” or “skewed to the right”, whereas a distribution with asymmetric tail extending out to the left is referred to as “negatively skewed” or “skewed to the left”. Skewness can range from minus infinity to plus infinity.

**Causes for skewed data.** Skewed data often occur due to lower or upper bounds on the data. That is, data that

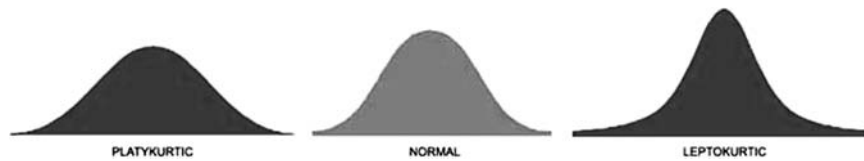

Figure 11. Different pattern of peakness.

have a lower bound are often skewed right, whereas data that have an upper bound are often skewed left.

### Kurtosis

Kurtosis is a measure of whether the data is peaked or flat relative to a normal distribution. Distributions having higher kurtosis with longer tails (more peaked than normal) or more extreme values are called as “Leptokurtic”, whereas those with lower kurtosis with fatter middles (more flat than normal) or fewer extreme values are called as “Platykurtic”. The normal pattern of distribution of data (bell shaped) is called as “Mesokurtic”.

For testing normality using skewness and kurtosis, the most commonly used tests is Pearson’s (1905) skewness and kurtosis tests. Skewness = 0 and kurtosis = 3 for normal distribution.

### Formal statistical tests

Among the formal methods of testing normality, Kolmogorov–Smirnov and Shapiro–Wilk are the most commonly employed method.

#### Kolmogorov–Smirnov test

Kolmogorov–Smirnov test can be applied to test whether the data follow any specified distribution, not just the normal distribution. As a general test, it may not be as powerful as a test specifically designed to test normality. Moreover, the Kolmogorov–Smirnov test becomes a conservative test (and thus loses power) if the mean and/or variance is not specified beforehand. And the Kolmogorov–Smirnov test will not indicate the type of non-normality, say whether the distribution appears to be skewed or heavy-tailed.

#### Shapiro–Wilk test

Shapiro–Wilk test is specially designed to detect the departures from normality, without requiring the mean or variance of the distribution. This test is more powerful than the Kolmogorov–Smirnov test.

### Assumptions of homogeneity of variance

Equal variances across the samples are called homogeneity of variance. Some statistical tests, for example, the *t*-test and ANOVA (analysis of variance), assume that the variances are equal across the groups or samples. The two commonly used methods for testing of equality of variance are Levene’s and Bartlett’s test.

### Independence assumption

Many test statistics assume that the sample observations are independent of each other.

### Randomness

Most of the statistics assume that the sample observations are random. Run test is used to test the assumption of randomness.

### Equality of means

Hotelling’s T-square test is used to test the multivariate test for the equality of mean assumption. An insignificant value of Hotelling’s T-square shows the equality of means.

### Multicollinearity

Multicollinearity means that the dependent variables have a perfect degree of correlation. To test the assumption of multicollinearity, VIF and condition indices are used.

## CONCLUSION

In this issue, we have seen various tools for testing of assumption. Many parametric tests (*t*-test, ANOVA, etc.) should follow the above-mentioned assumptions. If the data do not meet the listed assumption, then use a non-parametric analysis or other relevant statistical tools.

Among the testing of assumptions, normality is the most commonly followed assumptions in the data analysis. In the next issue, we will discuss about concept of correlation analysis.

---

#### Testing of assumptions—testing of normality

---

Graphical method	Mathematical method
a. Box plot	1. Kolmogorov–Smirnov
b. Histogram	2. Shapiro–Wilk
c. P–P plot	
d. Q–Q plot	
e. Skewness	
f. Kurtosis	

---

## REFERENCES

1. Chan YH. Biostatistics 101: data presentation. Singapore Med. J. 2003; 44(6): 280–5.
2. Shapiro SS, Wilk MB. An analysis of variance test for normality (complete samples). *Biometrika* 1965; 52(3/4): 591–611.
3. Trosset MW. An introduction to statistical inference and data analysis. April 3: 2001.
4. [www.childrens-mercy.org/stats/definition/boxplot.htm](http://www.childrens-mercy.org/stats/definition/boxplot.htm).5.

# Toxic anterior segment syndrome (TASS)

Mohammad Arif

*C.U. Shah Post Graduate Ophthalmic Institute*

TASS is an acute postoperative inflammatory reaction in which a noninfectious substance enters the anterior segment and induces toxic damage to the intraocular tissues.

Previously this syndrome was called 'Sterile endophthalmitis' or 'postoperative uveitis of unknown cause'. Furthermore, a condition termed toxic endothelial cell destruction (TECD) syndrome has been described and is now believed to be a variant of TASS.

## Pathophysiology

TASS results from the inadvertent entry of toxic substances into the anterior chamber. This causes a marked inflammatory reaction that varies in intensity and can induce permanent corneal endothelial and trabecular meshwork damage.

## Clinical features

In the setting of postoperative inflammation, distinguishing TASS from infectious endophthalmitis is very important because both conditions can present in a similar fashion. (Table 1).

Features that are unique to TASS include the following:

- Limbus-to-limbus corneal edema is considered to be the classic finding of TASS; however, not all cases have this finding. Most frequently, the occurrence appears as a milder form with increased anterior chamber cells in excess of that seen following surgery.
- Anterior chamber reaction can be moderate to severe with the presence of hypopyon and fibrin. Unlike infectious endophthalmitis, vitreous inflammation is rare, and, if it occurs, it is considered to be the result of a posterior diffusion from the anterior chamber.
- An unreactive dilated pupil may be noted.
- The intraocular pressure can be elevated secondary to trabecular meshwork damage.
- Cystoid macular edema has been reported in a few cases.

## Etiological agents

- Extraocular substances that inadvertently enter the anterior chamber
  - Topical antiseptic agents
  - Talc from surgical gloves
- Products that are introduced into the anterior chamber as part of the procedure
  - Anaesthetic agents (e.g., lidocaine 2% vs. 1%)
  - Preservatives (e.g., benzalkonium chloride)
  - Inappropriately reconstituted intraocular preparations

- Contaminated irrigating solutions (e.g., BSS with bacterial endotoxin)

- Contaminants on the surfaces of intraocular surgical instruments that have accumulated as a consequence of inappropriate instrument cleaning
- Denatured viscosurgical devices
- Enzymatic detergents

Because of the multiple causes it is often difficult for the surgical center to isolate a cause directly.

## Investigations

- In case of doubt, A.C aspirate, a vitreous tap for PCR, Gram stains and microbiologic cultures is done.
- USG B scan if media is hazy

## Differential Diagnosis

Endophthalmitis, Postoperative (Bacterial).  
Postoperative uveitis secondary to retained lens materials & viscoelastics.

## Treatment

### Medical

- Patients should be treated as if infectious endophthalmitis is present if the clinical picture is unclear as to the exact etiology of the inflammation.
- Once TASS is confirmed, patients should be started on topical steroids. The usual regimen is Prednisolone acetate 1% eye drop every 30-60 minutes with gradual tapering. Patients should be reassessed later the same day.
- Careful assessment and treatment of elevated intraocular pressure is important to prevent optic nerve damage.
- Nonsteroidal anti-inflammatory drops have been shown to be a helpful adjunct in several cases of TASS.

### Surgical

- No clear benefit has been demonstrated for immediate anterior chamber washout.
- In cases where the intraocular lens is suspected to be the cause of the inflammation, an intraocular lens exchange may be needed if no response to medical treatment is demonstrated.
- If corneal edema persists for more than 6 weeks despite medical treatment, the corneal decompensation is likely permanent and a corneal transplantation is required.
- If intraocular pressure cannot be controlled medically, filtering procedures may be required.

Table 1. Differences between TASS &amp; Infectious endophthalmitis

Sl No.	Clinical Features	TASS	Infectious Endophthalmitis
1	Onset	12 to 24hr	2 days to 7 days
2	Pain	None/Mild	Severe
3	Visual acuity	Decreased	Decreased
4	Lid Swelling	Not evident	Often present
5	IOP	May be elevated	Usually not elevated
6	Corneal edema	Limbus to limbus	Often confined to site of entry
7	AC reaction	Moderate to severe	Moderate to severe
		Hypopyon may be present	Hypopyon often present
8	Pupil	Fixed and dilated	Reactive
9	Vitritis	Very rare	Always present
10	Response to Steroids	Dramatic improvement	Equivocal

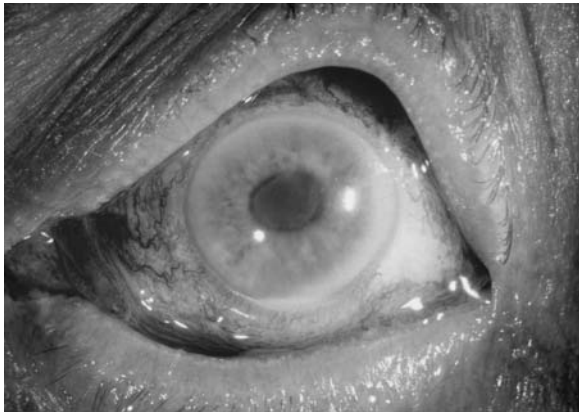


Figure 1. Slit lamp picture showing diffuse limbus-to-limbus corneal edema and anterior segment inflammation noted in a patient with toxic anterior segment syndrome (TASS).

### Prevention

The following suggestions are helpful in reducing the incidence of TASS:

- All preoperative, intraoperative, and postoperative steps at the surgical theatre should be thoroughly assessed,
- Reusable instruments should be kept to a minimum, particularly those at high risk for contamination (e.g., cannulas).
- Nondisposable instruments should be thoroughly rinsed with sterile, deionized water.
- Document the specific lot number of all products coming in contact with the eye. This should include all viscoelastic material, IOLs, solutions, and medications injected and irrigated (such as lidocaine, epinephrine, and topical IOL)
- Keep a record of staff who works on each surgical case, including surgeons, nurses, anaesthesiologists and those who process instruments.

- Ultrasound water baths should be replaced daily.
- Weekly replacement of the water reservoir for steam autoclave sterilizers is important to reduce the risk of bacterial endotoxin build up.
- Care should be taken to check that the intraocular medications used during surgery are preservative-free and at the proper intraocular drug concentration.
- A complete review of operating room protocols should be undertaken by the surgeon, nursing staff, and all personnel working in the operating room.

### REFERENCES

1. Moshirfar M, Whitened G, Beutler BC, et al. Toxic anterior segment syndrome after Verisyse iris-supported phakic intraocular lens implantation. *J Cataract Refract Surg* 2006; 32:1233-1237.
2. West ES, Behrens A, McDonnell PJ, et al. The incidence of endophthalmitis after cataract surgery among the US Medicare population increased between 1994 and 2001. *Ophthalmology* 2005; 112:1388-1395.
3. Wallin T, Parker J, Jin Y, et al. Cohort study of 27 cases of endophthalmitis at a single institution. *J Cataract Refract Surg* 2005; 31:735-741.
4. Holland SP, Morck DW, Chavez G, Lee TL. Toxic anterior segment syndrome. Agarwal A. *Refractive surgery nightmares: conquering refractive surgery catastrophes*. Slack: Thorofare 2006; in press.
5. Mamalis N, Edelhauser HF, Dawson DG, et al. Toxic anterior segment syndrome. Review/update. *J Cataract Refract Surg* 2006; 32:324-333.
6. Breebaart AC, Nuyts RMMA, Pels E, et al. Toxic endothelial destruction of the cornea after routine extracapsular cataract surgery. *Arch Ophthalmol* 1990; 108:1121-1125.
7. Liu H, Routley I, Teichmann KD. Toxic endothelial cell destruction from intraocular benzalkonium chloride. *J Cataract Refract Surg* 2001; 27:1746-1750.
8. Eleftheriadis H, Cheong M, Saneman S, et al. Corneal toxicity secondary to inadvertent use of benzalkonium chloride preserved viscoelastic material in cataract surgery. *Br J Ophthalmol* 2002; 86:299-305.
9. Van Gelder RN. Applications of the polymerase chain reaction to diagnosis of ophthalmic disease. *Surv Ophthalmol* 2001; 45:248-258.



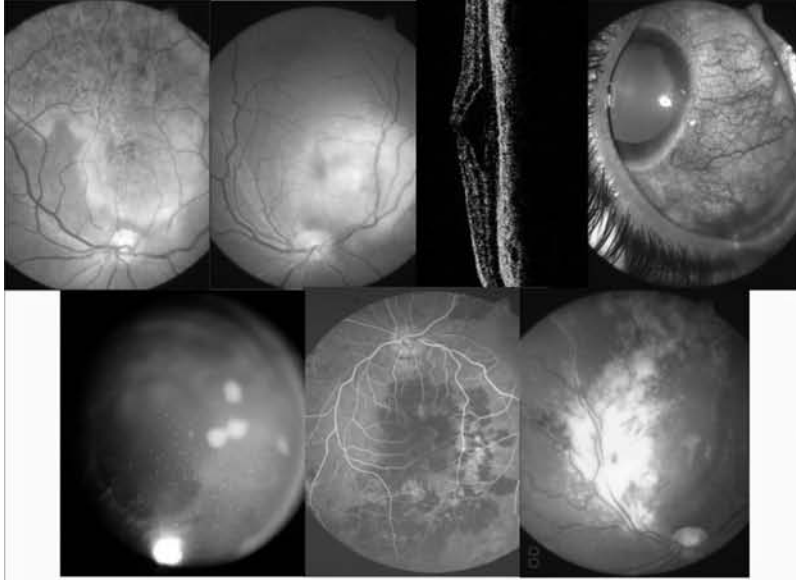
## *How you can Donate in the United States*

Sankara Nethralaya OM Trust Inc.  
9710 Traville Gateway Drive, No. 392  
Rockville, MD 20850, Ph: (877) 393-7666  
Tax Exempt ID No. 52-1611548

- **United Way** - Mention the above information on your authorization form. Local chapters will remit your contributions to SN OM Trust Inc.
- **Combined Federal Campaign** - If you a US federal employee, make your donations to Sankara Nethralaya OM Trust Inc. CFC No. 68803. We are listed under international independent agencies.
- **Employer Matching Program** - Check with your Human Resources Office if they participate in employer gift matching program. Number of US employers match dollar for dollar for employees' contributions. You may able to double your contributions to SN OM Trust.
- **Credit Card Donations** - Go to our website [www.omtrust.org](http://www.omtrust.org), click on 'Donate Now' button and follow the self explanatory instructions.
- **Draft from Checking Account** - Download Direct debit authorization form from the home page of our web site [www.omtrust.org](http://www.omtrust.org). Complete the form and forward your authorization with a 'void check' to the above address. We will draft the funds on 15<sup>th</sup> of every month. You can stop your authorization any time by a simple notification to us.
- **Appreciated Stocks** You may donate appreciated stocks to SN OM Trust Inc and avail a tax deduction. For additional information, please contact the Trust at the aforementioned phone number.
- **Payroll Deductions** - Please check with your HR office if they are programmed to withhold from payroll and remit to non profit organization. Number of organizations provide this as a public service.
- **Contributions by check** - Simply make your check payable to SN OM Trust Inc. and mail to the above address.

For additional information, contact –

K.G. Venkataraman [kvenkatram@aol.com](mailto:kvenkatram@aol.com), S. Kannappansam [kannappan@gmail.com](mailto:kannappan@gmail.com)  
Shankar Iyer [sai@omtrust.org](mailto:sai@omtrust.org) S.V. Acharya [acharya@omtrust.org](mailto:acharya@omtrust.org)



**Registration Form**

Name : Dr/Mr/Ms: .....

Contact Address: .....

.....

.....

E-mail ID: .....

Mobile No: .....

Please find enclosed my DD No ..... for Rs. .... towards registration.

Dated: ..... for Rs. .... towards registration.

DD should be drawn in favour of : Medical Research Foundation, Chennai, and mailed to the organising secretary.

**Early bird Registration fee : Rs 1500**

**Early bird Registration ends: October 31, 2009**

**Late/Spot registration : Rs 2000**

**Accommodation & Travel**

**The DMC**

Mr. Sonai Elankumaran

Mobile : 9789096534

Email : sales@tdmcindia.com

**Organising Team**

Jyotirmay Biswas

Sudha K Ganesh

Amala E George

Mamta Agarwal

Sudharshan S

Amitabh Kumar

Suchitra Pradeep

**Organising Secretary**

Dr Jyotirmay Biswas

Director and Head

Department of Uveitis and Ocular pathology

Medical and Vision Research Foundation

Sankara Nethralaya, Chennai - 600 006

Ph - +91-44-28271616, Mobile : 9841428151

Email : drjb@snmail.org



# 9th Annual Meeting Uveitis Society Of India

**December 4th, 5th & 6th 2009**

**Sankara Nethralaya,  
Chennai, India**

[www.usichennai2009.org](http://www.usichennai2009.org)

[www.usichennai2009.org](http://www.usichennai2009.org)